

## **6th Annual EFCS Tutorial, Guimarães, Portugal**

---

### **Non-gynaecological cytology II**

**Helena Oliveira**

Biliary tract cytology

2-9

**Ricardo Fonseca**

Pancreas cytology

10-25

**Ashish Chandra**

Fine needle aspiration cytology of salivary gland  
lesions: clinical aspects and diagnostic pitfalls

25-32

**Helena Barroca**

Paediatric cytopathology

33-72

### **TO FOLLOW**

**Ambrogio Fassina**

Respiratory tract cytology (including EBUS)

**Mufaddal Moonim**

Lymph nodes and lymphoma

# BILIARY CYTOLOGY

## Helena Oliveira

HPP Hospital de Cascais, Alcabideche, Portugal

Email: mariahelenasousaoliveira@gmail.com

---

### Normal anatomy and histology

The **gallbladder** is a pear-shaped sac attached to the posterior aspect of the right hepatic lobe. It is divided in *fundus*, *body*, and *neck*. The portion of the body that joins the neck is referred to as the *infundibulum*; sometimes there is a small bulge in this portion, known as *Hartmann pouch*, which some authors claim to be an acquired configuration due to inflammatory processes.

The mucosa is made up of variably sized branching folds lined by a single layer of columnar cells having a pale cytoplasm with occasional small apical vacuoles and basally located nuclei.

Smaller, darkly staining columnar cells have been called '*pencil-like*' cells. Basal cells are inconspicuous, and myoepithelial cells are absent.

In the gallbladder, true glands are present only in the neck. They are of the tubule-alveolar mucous type and differ from the antral-type metaplastic glands found throughout the gallbladder in cases of chronic cholecystitis or cholelithiasis. Scattered neuroendocrine cells may be found.

Histochemically, the mucin produced by both the lining cells and the neck mucous glands is mainly of sulfated acid type (in contrast to that of metaplastic glands).

Immunohistochemically, both cell types are reactive for epithelial membrane antigen (EMA) and low molecular weight keratin.

**Extrahepatic biliary system** is composed of the *cystic*, *hepatic (right, left, and common)*, and *common bile ducts*. The lining of the cystic duct is pleated, with large oblique folds containing smooth muscle (*spiral valves of Heister*). Numerous variations in the anatomy of these ducts and their blood supply occur.

the lining of all the extrahepatic ducts is made up of a single layer of columnar cells resting on dense connective tissue. This epithelium penetrates into the stroma to form pits known as the *sacculi of Beale*, the larger of which can be seen grossly. Surrounding these sacculi are small

glands that are surrounded by dense stroma and may mimic well-differentiated carcinoma; their lobular architecture seen on low-power microscopy is the most important identifying feature.

Histochemically, and immunohistochemically, the lining epithelium of the extrahepatic ducts is qualitatively similar to that of the gallbladder.

### **Collecting methods and types of samples**

Biliary duct lesions generally are not accessible to biopsy. Although some techniques have been developed to reach lesions with small forceps.

**Duodenal contents** were used since 1920 for cytological analysis but with low sensitivity. **Collecting bile and pancreatic juice** was possible through endoscopic retrograde cholangiopancreatography. The samples have low cellularity and show artefacts from degenerative changes, rendering a low sensitivity.

**Cytology samples from extracted stents and stent retrieval devices** have low sensitivity for the same reasons.

**Biliary duct brushing** is an adjuvant procedure to endoscopic retrograde cholangiopancreatography (ERCP), a technique that combines endoscopy and fluoroscopy. It collects cells for cytological diagnosis and ancillary testing. This is the most widely used technique in the diagnosis of biliary strictures.

Brush cytology allows direct sampling of the lesion and strictures, nevertheless these can be hindered by tumour desmoplasia, sub mucosal location of tumours or compression of extrinsic tumours.

The combination of smears and liquid based cytology improves general accuracy that has been reported to be 75.7% with 52.6% sensitivity, 99.4% specificity, 98.9% positive predictive value, 67.1% negative predictive value. Factors that influence the results are interpathologist variation of interpretation and clinical information. Most false negative results are sampling errors followed by interpretative and technical errors.

### **APPLICATIONS**

This technique is most useful to study extra-hepatic biliary and pancreatic obstructions. The more frequent symptom related is jaundice. Abnormalities of the extrahepatic biliary tract can be

caused by inflammatory processes, malignancy, and calculus, diseases that should be accurately diagnosed prior to therapy. Most benign strictures are managed conservatively with ductal dilatation and stenting while malignant strictures may be treated by Whipple procedure, bile duct resection, or simple stenting if the patient's disease is unresectable. Recent advances in neoadjuvant chemo- and radiotherapeutic approaches underscore the importance of accurate preoperative diagnosis.

### **Normal cytology**

- High and low columnar cell
- Bilirubin, cholesterol and calcium carbonate crystals
- Honeycomb sheets of cells in single layers
- Round or ovoid nucleus, with one or two nucleoli
- Small cytoplasmic vacuoles
- Stromal fusiform cells, with dense slender nucleus
- Scarce inflammatory cells

### **Pathology**

Strictures

Inflammatory

- Calculus
- Acute inflammation
- Chronic inflammation
- Infestations

Tumors

- Benign epithelial tumours
  - Adenomas and papillomas
  - Cystadenomas
  - Dysplasia and carcinoma in situ
- Malignant epithelial tumors
  - Adenocarcinoma

## Variants

Papillary carcinoma

Adenosquamous and squamous cell carcinoma

Carcinomas with neuroendocrine differentiation

Intestinal-type adenocarcinoma

Clear cell carcinoma

Diffuse infiltrative (signet ring cell) adenocarcinoma

Undifferentiated sarcomatoid carcinoma (with or without osteoclast-like giant cells)

Lymphoepithelioma-like carcinoma and medullary carcinoma

Hepatoid carcinoma

Mucinous carcinoma

Cystadenocarcinoma

## Neuroendocrine tumors

Carcinoid tumor (well-differentiated neuroendocrine tumor)

Paraganglioma

## Mesenchymal tumor

Granular cell tumor

Embryonal rhabdomyosarcoma

## Secondary tumours

Hematopoietic malignancies

Melanoma

The risk of developing carcinoma in adenomas is not as strong as flat dysplasia/carcinoma in situ.

On the majority of the samples, the main differential diagnosis is benign versus malignant strictures in a patient presenting with jaundice, being adenocarcinoma the most frequent malignant diagnosis.

## **CHOLANGIOCARCINOMA - CLINICAL FEATURES**

Cholangiocarcinoma is the second most common hepatobiliary tumour and incidence is rising worldwide. It occurs in approximately 2 per 100 000 people and account for approximately 13% of primary liver cancers.

Chronic biliary tract inflammation represents a major risk factor for the development of cholangiocarcinoma (ex: chronic parasitic infection of the biliary tract, primary sclerosing cholangitis).

There has been a marked global increase in mortality from intrahepatic, but not extra-hepatic, biliary tract malignancies.

Approach to liver nodules suspected of malignancy are usually sampled for cytological diagnosis by transabdominal FNA (fine needle aspiration) or EUS-FNA (endoscopic ultrasound fine needle aspiration) if their location is in the left lobe.

Cholangiocarcinomas of extra-hepatic bile ducts, if they are not mass forming, most probably will be sampled by brush cytology during Endoscopic Retrograde Cholangiopancreatography (ERCP).

## **CYTOLOGICAL FEATURES**

**Brush cytology** samples represent the whole content of ducts so they will have:

- cellular debris, biliary pigment and crystals
- epithelial disorganized flat sheets, three dimensional groups or clusters
- single cells, small acinar clusters, loose aggregates, papillary and cell in cell groups
- high N:C ratio, coarse chromatin and prominent nucleoli, nuclear clearing.
- signet ring cells

**FNA** samples will contain contaminants from the organs adjacent when using EUS-FNA, which can be a pitfall on interpreting smears. Intra-hepatic cholangiocarcinomas will show :

- glandular cells in flat angulated sheets
- single cells
- Increased n:c ratio

- nuclear overlapping, irregular nuclear membrane and chromatin clearing
- visible nucleoli, some prominent
- atypia may range from markedly malignant cells to border-line appearance
- stroma and mucin can be seen.
- 

### IMMUNOPHENOTYPE

Cytokeratins (CK) 7 and 19 are positive and CK20 is negative. Polyclonal CEA marks diffusely the cytoplasm. LeuM1 and B72.3 are positive.

**Differential diagnosis** on brush cytology is with benign lesions, adenomas and atypia from inflammatory strictures, which can mimic malignancy on cytology. Moreover, malignancy can arise in a set of inflammation. Low grade neoplasia and reactive changes can be very difficult to differentiate.

	Single cells	Groups of cells
Atypia/reactive	+	Flat plaques
Adenocarcinoma low-grade	+++	Three dimensional groups

Rare tumors may appear like granular cell tumors, carcinoid, squamous and mixed squamous carcinoma. Also metastatic tumors must be considered if the cytological features are unusual.

**Modified diagnostic criteria for reactive change of the biliary epithelium and biliary intraepithelial neoplasia (from: *Biliary intraepithelial neoplasia: an international interobserver agreement study and proposal for diagnostic criteria - Modern Pathology 2007; 20:701-9*)**

**Hyperplasia or regenerative change**

These lesions are most commonly flat. Low-papillary or micropapillary architecture, when observed, are often associated with hepatolithiasis or choledochal cyst, but tall papillary structures are rare. Cellularity is only slightly increased compared to normal biliary epithelium. Nuclei are round or oval, and slightly enlarged with smooth nuclear membrane. Chromatin is fine and homogeneously distributed. Intraepithelial neutrophil infiltration can be seen. Mitoses can be observed in some lesions. (\*)

**BIIN-1 (biliary intraepithelial neoplasia-1)**

These lesions show flat or micropapillary architecture. Nuclei are basally located. Some lesions show focal nuclear pseudostratification; however, the nuclei remain within the lower two thirds of the epithelium. Cytologically, mild nuclear abnormalities, such as subtle irregularities of nuclear membrane, high nuclear/cytoplasmic ratios and nuclear elongation are seen. Nuclear sizes and shapes are relatively uniform, and the presence of large nuclei suggest a diagnosis of BIIN-2 or BIIN-3.

**BIIN-2 (biliary intraepithelial neoplasia-2)**

These lesions show flat, pseudopapillary or micropapillary architecture. Loss of cellular polarity is easily found, but it is not a diffuse feature. Nuclear pseudostratification reaching the luminal surface is common. Cytologically, dysplastic nuclear changes, which include enlargement, hyperchromasia and irregular nuclear membrane, are evident. Some variations in nuclear sizes and shapes are seen. Peribiliary glands are sometimes involved (glandular involvement). Mitoses are rare.



### **BilIN-3 (biliary intraepithelial neoplasia-3)**

These lesions usually show pseudopapillary or micropapillary architecture, and are only rarely flat. They cytologically resemble carcinoma, but invasion through the basement membrane is absent. Cellular polarity is diffusely and severely distorted with nuclei reaching and piling on the luminal surface. ‘Budding off’ of small clusters of epithelial cells into the lumen and cribriforming can be seen. Cytologically malignant features with severe nuclear membrane irregularities, hyperchromasia or abnormally large nuclei are typically noted. Mitoses can be observed. Peribiliary gland involvement is sometimes found.

*(\*) When present, discrimination from BilIN is important, because mitoses in BilIN suggest the diagnosis of higher grade lesions, mostly BilIN-3.*

### **References**

Keith E. Volmar, Robin T. Vollmer, Mark J. Routbort, Andrew J. Creager. Pancreatic and Bile Duct Brushing Cytology in 1000 Cases - Review of Findings and Comparison of Preparation Methods, *CANCER (CANCER CYTOPATHOLOGY)* August 25, 2006 / Volume 108 / Number 4

Gabrijela Kocjan, (2010). Gall Bladder and extrahepatic bile ducts. In Winifred Gray and Gabrijela Kocjan (Ed.), *Diagnostic Cytopathology* 3th edition, Chapter 9, Section 6 Hepatobiliary System and Pancreas (pp 319-321)

Roberto Logrono, Daniel F. Kurtycz, Claudia P. Molina, Vipul A. Trivedi, Jick Y. Wong, and Kevin P. Block (2000) Analysis of False-Negative Diagnoses on Endoscopic Brush Cytology of Biliary and Pancreatic Duct Strictures. *Archives of Pathology & Laboratory Medicine*: March 2000, Vol. 124, No. 3, pp. 387-392.

Barbara A. Centeno (2009) CHAPTER 30–Diagnostic Cytology of the Biliary Tract and Pancreas in *Surgical Pathology of the GI Tract, Liver, Biliary Tract and Pancreas*, 2nd Edition. Edited by Robert D. Odze, MD, FRCP(C) and John R. Goldblum, MD, FCAP, FASCP, FACG

Laura M. Stinton and Eldon A. Shaffer - Epidemiology of Gallbladder Disease: Cholelithiasis and Cancer; *Gut Liver* 2012;6:172-187

Zen Y, Adsay V, Bardadin K *et al.* Biliary intraepithelial neoplasia: an international interobserver agreement study and proposal for diagnostic criteria; *Modern Pathology* (2007) 20, 701–709.

## **Pancreatic FNA cytology**

### **Ricardo Fonseca**

Instituto Português de Oncologia de Lisboa Francisco Gentil, Portugal

Email: ricardo.fonseca@netcabo.pt

---

#### **Objectives:**

- Recognize GI contamination from EUS-FNA
- Identify the cytological criteria for the diagnosis of pancreatic adenocarcinoma, pancreatic endocrine neoplasm, solid pseudopapillary neoplasm, and various pancreatic cysts.
- Understand the ancillary tests useful in the differential diagnosis of selected neoplasms.
- Understand the benefits and limitations of ancillary tests such as mucin stains, cyst fluid analysis and molecular analysis in the cytological evaluation of pancreatic cysts.

#### **Possible contaminants of pancreatic EUS-FNA**

Mesothelial cells (percutaneous approach)

- Two-dimensional flat sheets
- Round-to-oval nuclei
- Moderate amount of pale cytoplasm
- Intercellular windows

Hepatocytes (percutaneous approach)

- Polygonal cells
- Abundant well-defined granular cytoplasm ( $\pm$  cytoplasmic pigments)
- Round-to-oval nuclei with prominent nucleoli

Bowel mucosa

Duodenal mucosa (endoscopic transduodenal approach for lesions in the pancreatic head and uncinata).

- Two-dimensional flat sheets with orderly “honeycomb” arrangement
- Variable number of single cells.
- Round, evenly spaced, and bland-appearing nuclei
- Pale cytoplasm with well-defined borders
- Intermixed goblet cells
- Frequently admixed with thin extracellular mucus.

Gastric mucosa (endoscopic transgastric approach for lesions in the pancreatic body and tail).

- Two-dimensional flat sheets with orderly “honeycomb” arrangement.
- Variable number of single cells.
- Round, evenly spaced, and bland-appearing nuclei
- Pale cytoplasm with well-defined borders
- Goblet cells rare except in intestinal metaplasia.
- Frequently admixed with mucin.
- Parietal cells may be seen.

**WHO classification of primary tumours of the exocrine and endocrine pancreas:**

- Ductal adenocarcinoma (and its variants).
- Acinar cell carcinoma / acinar cell cystadenocarcinoma <sup>1</sup>
- Intraductal papillary mucinous neoplasm (IPMN) <sup>2</sup>
- Mucinous cystic neoplasm <sup>2</sup>
- Neuroendocrine neoplasm <sup>3</sup>
- Serous neoplasm <sup>4</sup>
- Pancreatoblastoma
- Solid-pseudopapillary neoplasm

1 – Acinar cell neoplasm can sometimes show mixed differentiation

2 – IPMN and mucinous cystic neoplasm are graded on the degree of

- intraepithelial atypia and may both be noninvasive or invasive.
- 3 – The WHO classifies pancreatic endocrine tumours according to their secretory peptides.
  - 4 – Serous neoplasm are almost always benign but may be malignant.

## **Topics**

### **I - Well-differentiated adenocarcinoma vs chronic pancreatitis**

Discussion: The primary differential diagnosis of a well-differentiated adenocarcinoma of the pancreas is chronic pancreatitis (CP). Gastrointestinal contamination is also a significant consideration, especially from the stomach. Both ductal adenocarcinoma and chronic pancreatitis are more common in the pancreatic head. Adenocarcinoma generally occurs in older individuals, usually by 20 years compared to CP (50 versus 70 years). A history of alcohol abuse and pancreatitis should raise one's threshold for a malignant diagnosis. Classic radiological images of chronic pancreatitis that demonstrate irregular ductal dilatation often associated with stricture formation, obstruction and calcifications, usually correlates with CP. Areas of expansive fibrosis within chronic pancreatitis mimicking a carcinoma presents the diagnostic uncertainty on EUS. On CT, carcinomas are poorly defined hypodense masses with central attenuation distorting the normal pancreatic lobulation and are often associated with an abrupt stricture in the main pancreatic duct. Dually dilated main pancreatic and bile ducts, the so called "double duct" sign within the pancreatic head, is a diagnostic clue. Loss of a tissue interface between the tumor and the large peri-pancreatic vessels (superior mesenteric or celiac axis) indicates invasion and stages the tumor as unresectable (pT4).

The distinction between benign and malignant on FNA smears is most challenging for well-differentiated neoplasms. For well-differentiated adenocarcinoma, overall cellular composition of the slide is important in distinguishing benign from malignant. Smears of carcinoma should be relatively pure with only ductal groups for carcinoma and little to no acinar epithelium. Smears containing acinar and endocrine cells should be interpreted with caution as this mixed cellular pattern is typical of pancreatitis. Similarly, the presence of granulation tissue and fibrous tissue fragments with inflammation are features associated with pancreatitis, and the cytological diagnosis of carcinoma in this setting is best restricted to

high-grade carcinoma only. Background coagulative (not saponified fat) necrosis and intact single atypical cells are features that support a malignant diagnosis.

The arrangement of the cells in groups and sheets is important in distinguishing benign from malignant. The architectural arrangement of carcinoma cells ranges from large crowded sheets to small three-dimensional clusters and balls of cells to single cells. Malignant nuclei are crowded, overlap, and have lost nuclear polarity or they display an uneven distribution in a sheet ("drunken honeycomb"). In contrast, benign nuclei of the pancreatic ductal epithelium and GIC maintain order, polarity, and a uniform distribution within the sheet or group. In addition, the nuclear chromatin in well-differentiated carcinoma often displays a pale nucleus owing to parachromatin clearing in contrast to the vesicular or even, slightly coarse chromatin pattern in reactive ductal epithelium. Single intact cells are common in poorly differentiated carcinoma, but even the scant presence of intact individual atypical epithelial cells in well-differentiated carcinoma is significant and supports a malignant interpretation.

### ***Cytopathologic Features: Well-differentiated Adenocarcinoma***

- Cellularity varies with degree of sclerosis
- Relatively pure population of ductal cells
- Loss of honeycomb architecture with nuclear crowding, overlapping and loss of polarity and uneven spacing ("drunken honey-comb")
- Irregular nuclear membranes often subtle with well-differentiated carcinoma
- Pale nuclei with parachromatin clearing
- Cytoplasm appears abundant and vacuolated

Immunostains that support a malignant interpretation include positive cytoplasmic staining for monoclonal CEA, CA 125, MUC1, MUC5AC, and nuclear staining with p53 in more than 20% of nuclei. Loss of cytoplasmic and nuclear reactivity with Smad4 (dpc4) is also supportive of malignancy. Analysis of staining profiles is best on cellblock preparations of cellular samples and should be interpreted with caution on hypocellular cellblock specimens and especially destained direct smears.

### ***Differential diagnosis of pancreatic ductal adenocarcinoma***

- Chronic pancreatitis
- Other epithelial neoplasms
  - acinar cell neoplasm
  - pancreatic neuroendocrine neoplasm
- Metastases

### **References:**

- Chhieng DC, Stelow EB. Pancreatic Cytopathology. Eds Springer 2007.
- Pitman MB. Cytology of the Pancreas. Diagnostic Cytopathology. Winiferd Gray and Gabrijela Kocjan, eds. Churchill Livingstone, London. 2010.
- Hruban RH, Pitman MB, Klimstra DS. Tumors of the pancreas. Atlas of tumor pathology, 4<sup>th</sup> series, Fascicle 6. American Registry of Pathology; Armed Forces Institutes of Pathology; Washington DC 2007.

## **II – Ductal adenocarcinoma variants - Undifferentiated carcinoma with osteoclastic type giant cells.**

***Discussion:*** Undifferentiated carcinoma with osteoclast-like giant cells is the currently accepted nomenclature that reflects the understanding that these tumors are fundamentally malignant epithelial neoplasms associated with benign appearing multinucleated giant cells that resemble the giant cells of a giant cell tumor of the bone. The presence of KRAS point mutations, and the association of many of these neoplasms with either conventional ductal adenocarcinoma or mucinous cystic neoplasms, is indicative of their epithelial differentiation. On histology and cytology, the tumor is composed of osteoclast-like giant cells and atypical to overtly malignant polygonal to spindle shaped epithelioid mononuclear cells. The malignant mononuclear cells are positive for cytokeratin, while the osteoclast-like giant cells are not. However, the cytokeratin reactivity is

variable and some tumor cells may demonstrate either limited reactivity or complete lack of keratin expression. Thus, the absence of cytokeratin expression does not exclude this diagnosis.

Cytological findings: Undifferentiated carcinoma with osteoclast-like giant cells

- Dual cell population
- Spindle to polygonal atypical epithelioid mononuclear cells
- Bland multinucleated osteoclast-like giant cells
- Osteoid may be present

Benign and malignant processes in which multinucleated giant cells are a prominent feature should be distinguished from this tumour. The primary differential diagnosis is with undifferentiated (pleomorphic) carcinoma of the pancreas. Although undifferentiated carcinoma of the pancreas may show overlapping features with UCOGCs, undifferentiated carcinomas contain giant cells predominantly with malignant nuclei and only rare benign appearing osteoclast-like giant cells in contrast to the benign appearing osteoclast-like giant cells predominating in UCOGC tumors. Other malignant tumors that may yield bizarre multinucleated malignant cells include metastatic anaplastic carcinoma of the thyroid, malignant melanoma, hepatocellular carcinoma, high grade sarcomas and trophoblastic tumors. Tuberculosis, fat necrosis, pseudocysts, fungal infections, and foreign body giant cell reactions are among the benign lesions in which multinucleated giant cells may be seen.

However, these benign entities are extremely rare in the pancreas and are not associated with the usually overtly malignant stromal mononuclear cells of UCOGC.

#### **References:**

- Layfield LJ, Bentz J. Giant-cell containing neoplasms of the pancreas: an aspiration cytology study. *Diagn Cytopathol* 2008;36(4):238-44.
- Sakai Y, Kupelioglu AA, Yanagisawa A, et al. Origin of giant cells in osteoclast-like giant cell tumors of the pancreas. *Hum Pathol* 2000;31(10):1223-9.

- Pitman MB. Cytology of the Pancreas. Diagnostic Cytopathology. Winiferd Gray and Gabrijela Kocjan, eds. Churchill Livingstone, London. 2010.
- Hruban RH, Pitman MB, Klimstra DS. Tumors of the pancreas. Atlas of tumor pathology, 4<sup>th</sup> series, Fascicle 6. American Registry of Pathology; Armed Forces Institutes of Pathology; Washington DC 2007.
- Molberg KH, Heffess C, Delgado R, Albores-Saavedra J. Undifferentiated carcinoma with osteoclast-like giant cells of the pancreas and periampullary region. Cancer 1998;82:1279-87.

### **III - Solid-pseudopapillary neoplasm**

#### **Discussion:**

This tumour, also referred to as Frantz's tumor, occurs predominantly in adolescent girls and young women with a mean age of 28 years, but a range of 7-79 years. Approximately 10% do occur in men, however. Many of the reports of solid-pseudopapillary neoplasms (SPNs) come from Asia, however without apparent ethnic predilection or association with genetic syndromes. This low grade primary pancreatic neoplasm accounts for 1% of all exocrine pancreatic neoplasms.

Radiologically SPNs are well-circumscribed, generally large tumors with variably solid and cystic components located throughout the pancreas, but often in the body and tail. This tumor is a low grade malignancy with metastases present in 10 to 15% of cases, but this neoplasm is an indolent tumor and long-term survival has been reported even in patients with metastases to the liver and peritoneum. Complete resection of node negative patients is considered curative. Despite the cystic nature of this neoplasm, the cytomorphology places it in the differential diagnosis with other solid cellular neoplasms like endocrine tumors and acinar cell carcinoma.

As the name suggests, the predominant histological patterns are solid and pseudopapillary, with the papillary areas resulting from degenerative change occurring in a fundamentally solid tumour with rich vasculature. The tumour is composed of small uniform cells that frequently loosely surround fibrovascular cores composed of variably myxoid stroma. The presence of such papillary fragments on FNA smears makes the diagnosis



straightforward. The smear background may be clean or filled with cyst debris. The vascular papillary cores may not be prominent or even present on FNA, however, yielding a solid cellular smear pattern very similar to an endocrine tumor, acinar cell carcinoma and pancreatoblastoma. Diagnosis in such cases rests with evaluation of the cellular features and in some cases immunohistochemistry. The cells of SPN are oval to round with uniform euchromatic nuclei without prominent nucleoli. Nuclear grooves and indentations are a characteristic findings. The cytoplasm is scant to moderate and may contain a perinuclear vacuole or a hyaline globule.

SPNs are variably positive with cytokeratin, but are often negative, and show nuclear reactivity with beta-catenin, membranous staining for CD10 and diffuse strong staining for vimentin. There is no staining with E-cadherin, while endocrine tumors show a membranous pattern of reactivity with both beta-catenin and E-cadherin. In conjunction with a negative chromogranin or synaptophysin stain, this pattern of immunoreactivity can definitively distinguish SPN from an endocrine tumor.

Cytological findings: Solid-pseudopapillary neoplasm

- Extremely solid cellular smear pattern cellular
- Papillary clusters with slender central fibrovascular cores with myxoid or collagenous stroma and loosely cohesive tumour cells
- Balls or globules of myxoid (metachromatic with Giemsa stains) stroma with or without a surrounding thick layer of neoplastic cells
- Papillary clusters with slender central fibrovascular cores with myxoid or collagenous stroma and loosely cohesive tumour cells
- Monomorphic round to oval nuclei with nuclear grooves, indentations and only slight pleomorphism
- Finely granular chromatin and small to no nucleoli
- Cytoplasm is pale and moderate in amount and may contain perinuclear vacuoles and hyaline globules
- Foamy macrophages and necrosis (evidence of cystic change)
- Perinuclear vacuoles and hyaline globules

Differential diagnosis

- Acinar cell carcinoma
  - cellular aspirate with single cells and loose clusters with the formation of acini.
  - Background: no necrosis or debris; naked nuclei.
  - neoplastic cells with abundant cytoplasm with indistinct cell borders
  - atypical central or eccentric nuclei with prominent nucleoli.

### Pancreatoblastoma

- cellular aspirates
- biphasic with epithelial stromal components
- epithelial component:
  - three-dimensional syncytial groups of intermediate-to-large pleomorphic cells
  - acinar structures composed of cells with more abundant cytoplasm and prominent nucleoli
  - squamoid corpuscles
- stromal component
  - primitive spindle-shaped cells
  - heterologous stroma, e.g., cartilage.

### Pancreatic endocrine neoplasms

- cellular aspirates
- loosely cohesive cell groups
- rosette or pseudorosette formation
- relatively uniform, round-to-polygonal tumour cells
- plasmacytoid cells
- salt-and-pepper chromatin
- may show: multinucleation; nuclear pleomorphism; mitosis; red cytoplasmic granules; naked nuclei, calcifications; amyloid deposition, necrotic debris.

## References

- Chhieng DC, Stelow EB. Pancreatic Cytopathology. Eds Springer 2007.
- Pitman MB. Cytology of the Pancreas. Diagnostic Cytopathology. Winifred Gray and Gabrijela Kocjan, eds. Churchill Livingstone, London.
- Hruban RH, Pitman MB, Klimstra DS. Tumors of the pancreas. Atlas of tumor pathology, 4<sup>th</sup> series, Fascicle 6. American Registry of Pathology; Armed Forces Institutes of Pathology; Washington DC 2007.
- Martin RC, Klimstra DS, Brennan MF, Conlon KC. Solid-pseudopapillary tumor of the pancreas: a surgical enigma? *Ann Surg Oncol* 2002;9(1):35-40.
- Tang LH, Aydin H, Brennan MF, Klimstra DS. Clinically aggressive solid pseudopapillary tumors of the pancreas: a report of two cases with components of undifferentiated carcinoma and a comparative clinicopathologic analysis of 34 conventional cases. *Am J Surg Pathol* 2005;29(4):512-9.

## IV - Multimodal Approach to Cytological Diagnosis of cystic lesion of the pancreas

Although cyst cytology alone is often non-diagnostic, when evaluated in the context of the clinical history, imaging features and gross cyst fluid appearance, special stains for mucin, biochemical testing for CEA and, amylase and increasingly molecular analysis, accuracy can be greatly improved. An educated and experienced cytopathologist is critical for accurate interpretation. The purpose of these pre-operative investigations is primarily to distinguish mucinous neoplasms from pseudocysts and serous cystadenomas, distinctions that directly affect patient management decisions.

## **Pseudocyst.**

Cytological findings: Pseudocyst

- Amorphous and cellular debris
- Mixed inflammatory cells
- Numerous macrophages, many with hemosiderin
- Epithelial cells should not be present (only contaminants).
- Cyst fluid analysis shows a markedly elevated amylase level with normal or slightly increased CEA concentration.

## **Intraductal neoplasms of the pancreas**

Intraductal papillary mucinous neoplasm (IPMN) and intraductal tubulopapillary neoplasms (ITPN) are defined as macroscopic epithelial neoplasms with ductal differentiation that characteristically grow primarily within the ductal system of the pancreas. These neoplasms due to their relatively slow-growing nature, often achieve fairly large sizes before they come to clinical attention, and both IPMN and ITPNs may be associated with (or progress to) invasive carcinoma.

The major features that distinguish these two groups of intraductal neoplasms are:

- 1) IPMNs are commonly associated with significant accumulation of mucin, whereas ITPNs have minimal luminal mucin and also lack obvious intracellular mucin.
- 2) Most IPMNs have a predominantly papillary growth patterns, whereas ITPNs are predominantly tubular architecture.
- 3) Grossly or histologically evident necrosis, often with a comedo-like pattern, may be found in ITPNs but is not typical of IPMNs
- 4) Immunolabelling of MUC5AC is common in IPMNs, but negative in the majority of ITPNs.

As there have been no systematic cytological or cyst fluid analyses in patients with ITPNs so we will focus on IPMNs.

**Intraductal papillary mucinous neoplasm (IPMN)** is a mucin producing neoplastic cyst that arises from and is directly connected with the pancreatic ductal system, either the main duct and/or side branch duct, and is lined by typically papillary and variably atypical mucinous epithelium. These neoplasms are not associated with subepithelial ovarian-type stroma as is required for the diagnosis of mucinous cystic neoplasm (MCN). Most IPMN occur in elderly men and women with a peak age of close to 65 years and a slight male predominance.

Prognosis is directly related to the presence or absence of an invasive carcinoma. As such, complete and thorough histological sampling is essential to rule out an invasive component given that these neoplasms tend to be very heterogenous in their lining, and that an invasive component may not be apparent grossly. Non-invasive IPMN have a greater than 90% 5 year survival rate, but this rate drops to 40% with invasive carcinoma, a rate that is still significantly better than conventional ductal adenocarcinoma.

Radiological and EUS features can be diagnostic when a markedly distended main pancreatic duct is noted to have filling defects or when there are multiple branch duct cysts. The visualization of copious amounts of mucin from a patulous ampulla is pathognomonic of IPMN. The appearance of an isolated branch duct IPMN, however, is almost impossible to distinguish from other cysts in the pancreas. Unlike mucinous cystic neoplasms (MCN) that are rare in the pancreatic head and uncinate process, branch duct IPMN cysts are non-septated, unilocular cysts often less than 5 cm that occur more commonly in the pancreatic head, especially the uncinate process. The recognition of an associated mural nodule is an independent predictor of malignancy.

The epithelial lining of IPMN includes gastric type, intestinal type, pancreatobiliary type and oncocytic type. Most main duct IPMN are lined by cells with intestinal differentiation, but branch duct IPMN are most commonly associated with gastric-foveolar type epithelium, the epithelial subtype least associated with carcinoma, hence the better prognosis of side branch duct IPMN compared to the main duct type. Distinguishing these varying types of lining epithelium in cytological preparations is not necessary. Distinguishing cyst lining epithelium from GI contamination is important. Consideration of cyst location, organ traversed and other clinical and radiological features makes the distinction possible in many cases.

FNA of IPMN produce variable amounts of mucin and cyst lining epithelium, and, as such, may not accurately reflect the histological grade of the cyst. A specific diagnosis of IPMN, therefore, is a less common cytological interpretation than a more general diagnosis of a neoplastic mucinous cyst that includes MCN. This is primarily due to hypocellularity of the mucinous contents aspirated and/or a lack of architectural specificity of the glandular epithelium, e.g. absence of papillary fragments. In addition, the lining of the cysts is often heterogeneous, so it is important to emphasize that regardless of the cytological diagnosis, a higher-grade neoplasm cannot be excluded. Thick and viscous, typically white cyst fluid grossly indicates mucin in most cases and, when reflected on the slide as a thick sheet of "colloid-like" mucin is diagnostic of a mucinous cyst regardless of the presence of an epithelial component. Gastrointestinal mucin may appear focally thick but not "colloid-like". Degenerated inflammatory cells and histiocytes within the mucin also helps to distinguish cyst mucin from contaminating mucin. Wisps of thick mucin with entrapped epithelial fragments with columnar cells displaying apical mucin cups should be interpreted as gastric contamination when aspirated from a cyst in the body or tail of the pancreas, but given that the gastricfoveolar type of lining is the most common type of lining in branch duct IPMN that most often occur in the pancreatic head, the typical transduodenal approach is not likely to produce foveolar appearing contamination. Thin, clear fluid may not be recognized at all if the fluid is processed by liquid based methods.

When processed as cytospin preparations, mucin stains (mucicarmin and/or Alcian blue pH 2.5) can help to identify and distinguish proteinaceous fluid from mucin. Negative mucin stains, however, do not exclude the diagnosis of IPMN. IPMN-adenoma typically produce scantily cellular aspirates composed of bland columnar mucinous glandular cells arranged in small clusters and flat to folded sheets with a honeycombed pattern. Clusters of columnar cells with round basal nuclei and mucinous cytoplasm are most often noted. Single cells may also be seen. Papillary epithelial fragments must be distinguished from villi of duodenal contamination for transduodenal EUS-guided aspirates. Recognition of intraepithelial lymphocytes and sporadically placed goblet cells supports duodenal epithelium, whereas the recognition of a mucinous luminal edge supports lesional epithelium. Single cells with visible mucinous cytoplasm also support lesional cells. Dense, oncocytic cytoplasm is consistent with intraductal oncocytic papillary neoplasm.

### **Cytological findings: IPMN with low- or intermediate grade dysplasia**

- Variable amounts of mucin
- Thick, colloid-like mucin with or without mucinous epithelium
- Thin, watery mucin
- Low cellularity
- +/- papillary fragments
- Mucinous glandular epithelium [with mucin occupying >1/3rd filling the columnar cytoplasmic compartment in transgastric FNAs]
- Absence of nuclear atypia
- No background necrosis

IPMN-high grade dysplasia/carcinoma are lined by atypical to malignant appearing glandular epithelium with variable amounts of cytoplasmic mucin. Although malignant IPMN typically have increased overall cellularity with respect to low-grade neoplasms, not all carcinomas produce cellular aspirates. In fact, the typical heterogeneity of these neoplasms may produce aspirate specimens with a range of cellular atypia from adenoma to carcinoma making accurate cytological diagnosis a challenge. Atypical cells display nuclear crowding, loss of polarity, nuclear elongation and hyperchromasia. Hyperchromatic cells with irregular nuclear membranes and high nuclear to cytoplasmic ratio may be arranged in elongated to papillary clusters where the length is usually twice the width of the group, small relatively bland epithelial cell clusters or singly. Even if very scant in amount, recognition of even one small group of such atypical epithelial cells is important for classifying the cyst as at least moderate dysplasia. Open chromatin, irregular nuclear membranes and nucleoli, significant background inflammation and necrosis supports the interpretation of an in situ or invasive carcinoma. Only necrosis appears to correlate with the presence of invasion, but this distinction cannot be made on aspirates of cyst contents alone. A mural nodule is indicative of an invasive carcinoma, and currently, aspiration of this nodule is necessary to cytologically document an invasive carcinoma.

### **Cytological findings: IPMN with high-grade dysplasia or more**

In addition to the above findings for IPMN with low grade dysplasia

- +/- Increased cellularity relative to adenoma
- Recognizable cytological atypia correlating with increased grade: single intact cells, doublets and small cell clusters, cellular papillary groups, nuclear irregularity, increased nuclear:cytoplasmic ratio, decreased cytoplasmic mucin, irregular nuclear membranes and nucleoli
- Abundant background inflammation and necrosis support malignancy

Cyst fluid analysis for CEA and amylase levels should be performed on all cyst fluids, and is especially important in the interpretation of cyst fluids that are thin and not grossly mucoid and likely to have few cells. CEA levels above 200 ng/ml are reported to distinguish non-mucinous from mucinous cysts with very high levels of CEA correlating with malignancy. Increasing the cut off value for CEA increases the specificity but decreases the sensitivity of the test. Amylase levels tend to be high in IPMN due to the connectivity of IPMN with the pancreatic duct, but amylase levels may also be high in MCN and pseudocysts so other factors need to be taken into consideration when making an overall interpretation. Molecular analysis of the cyst fluid demonstrating K-ras and LOH mutations also supports an interpretation of a mucinous cyst with malignancy correlating with elevated quantity DNA, KRAS 2-gene mutation and/or with numerous LOH mutations. Further validation of the diagnostic utility of molecular testing of pancreatic cyst fluid is needed.

IPMN involving the main duct solely, or in combination with one or more branch duct cysts is relatively specific for the radiological diagnosis. Branch duct IPMNs most often need to be distinguished from pseudocysts, gastrointestinal duplication cysts, macrocystic serous cysts and secondarily cystic solid neoplasms, especially cystic endocrine neoplasms.

### **Diagnostic pitfalls IPMN**

- Scant and under-representative sample
- Thin or non-detectable mucin



- Obscuring inflammation, necrosis and debris
- Gastrointestinal contamination in EUS guided aspirates.
- Low CEA levels
- Peri-pancreatic cysts such as duplication cysts
- Secondarily cystic solid neoplasms

## References

- Hruban RH, Pitman MB, and Klimstra DS. Tumors of the Pancreas. Atlas of Tumor Pathology, 4<sup>th</sup> series, fascicle 6. 2007, Washington, D.C.: American Registry of Pathology; Armed Forces Institutes of Pathology.
- Khalid A and Brugge W. ACG practice guidelines for the diagnosis and management of neoplastic pancreatic cysts. Am J Gastroenterol 2007; 102(10):2339-49.
- Pitman MB and Deshpande V. Endoscopic ultrasound-guided fine needle aspiration cytology of the pancreas: a morphological and multimodal approach to the diagnosis of solid and cystic mass lesions. Cytopathology 2007; 18(6):331-47.
- Pitman MB. Cytology of the Pancreas. Diagnostic Cytopathology. Winiferd Gray and Gabrijela Kocjan, eds. Churchill Livingstone, London. 2010
- Pitman MB. Revised international consensus guidelines for the management of patients with mucinous cysts. Cancer Cytopathol 2012 Dec 25;120(6):361-5.
- Pitman MB, Centeno BA, Genevay M, Fonseca R, Mino-Kenudson M. Grading epithelial atypia in endoscopic ultrasound-guided fine-needle aspiration of intraductal papillary mucinous neoplasms: An international interobserver concordance study. Cancer Cytopathol 2013 Jul (Epub ahead of print).

# **Fine needle aspiration cytology of salivary gland lesions: clinical aspects and diagnostic pitfalls**

**Ashish Chandra**

Guy's & St Thomas' NHS Foundation Trust, London, UK. Email: ashish.chandra66@gmail.com

---

## **Introduction**

The earliest account of salivary gland cytology dates back to the 1920s through Stewart's writing of his experience at the Memorial Hospital, New York when he stated that 'parotid tumours are particularly suited to aspiration' (Stewart, 1933). Further pioneering work came from the Karolinska Institute, Sweden in the 1960s (Linsk et al, 1985).

## **FNA and other biopsy techniques**

Today, cytopathologists use smaller gauge needles (23-26G) with increasing application of ancillary testing and closer correlation with clinical findings. The use of small gauge needles has minimized the risks of bleeding and tumour seeding. Early reports relating to seeding of tumour cells involved larger gauge needles and core biopsy needles. FNA is the sampling method of choice for cysts and when material is required for microbiology or flow cytometry. Its use in diagnosis of palatal, oropharyngeal and buccal nodules is also well established and safe (Saleh HA et al, 2008).

The dermatological punch biopsy may also be used for intraoral lesions. A 3 or 4mm punch if introduced to the centre of the lump retrieves a core of tissue and does not violate the tumour margin and consequently does not interfere with subsequent surgical removal. It is a very useful technique in the mouth where the lump lies close to the surface and dissipation of tumour into the subcuticular tissues is unlikely.

Core biopsy of the salivary gland may also be used with ultrasound guidance successfully in parotid swellings although this is often resorted to because of relatively poor results with FNA as shown in one recent study with a non-diagnostic rate of 25.8% (Pratap et al, 2009). In another study, the 18G needle biopsy was recommended for accurate diagnosis of parotid masses, which obviated the need for a frozen section in 31 cases (Wan et

al, 2004). The majority of salivary gland swellings can be adequately assessed with ultrasound and ultrasound guided FNA (Isa 2009).

Although FNA cytology has been shown to be a cost-effective, reliable technique its accurate interpretation depends on obtaining adequately cellular samples prepared to a high standard. Its accuracy and cost-effectiveness can be seriously compromised by inadequate samples. The best results are obtained when a pathologist or an experienced and trained biomedical scientist (cytotechnologist) provides immediate on-site assessment of sample adequacy (Kocjan et al 2009).

In a study from a single academic centre in the USA, the overall accuracy in distinguishing benign from malignant lesions was 79.1%, and the sensitivity of FNA for salivary neoplasia was 89.4% (Zhang et al 2009).

According to a study from Belfast, the overall cost of the FNA per episode in the out-patient clinic was £114 per episode compared to day case open biopsy per patient of £333 and an in-patient stay per patient was £2371. FNA provided sufficient pathological diagnosis to avoid day case surgery in 57 patients (42.2%), and inpatient surgery in 65 patients (48.1%) resulting in a total saving of £158,372 in 2004. (O'Donnell 2009).

### **Staining techniques**

Onsite assessment has distinct advantages in FNA of salivary gland lesions. It offers not only evaluation of the adequacy of the specimen but also allows a provisional diagnosis to be made with the opportunity of first-hand clinical history taking and examination by the cytopathologist. There is also the advantage of collecting material for ancillary testing such as microbiology, flow cytometry, immunocytochemistry and molecular testing.

Romanowsky stains such as Diff-Quik, Hemacolor are most commonly used with additional slide prepared for Papanicolaou (Pap) staining in the lab. The former displays the metachromatic stroma and cytoplasmic features well while the Pap stain offers the advantage of nuclear detail, thus complementing the former in cytodagnosis. In addition, the Pap stain helps in the confirmation of squamous differentiation.

FNA of the salivary gland is particularly good in confirming the diagnosis of a typical pleomorphic adenoma, granulomatous inflammation and metastatic malignancy. However, the distinction between benign and malignant counterparts (adenoma vs carcinoma) of a given tumour type is

not always possible on either FNA or core biopsy. Some of the well-recognised pitfalls are considered below.

### **Malignant transformation in pleomorphic adenoma**

The transformation into malignancy may be focal and missed on sampling of a large tumour. Variable degrees of atypia may be seen in a benign pleomorphic adenoma, however, the presence of necrosis or abnormal mitotic figures should raise the suspicion of malignancy.

### **Basal cell tumours**

A typical area of diagnostic difficulty lies in the distinction between basal cell tumours, basal cell adenoma and basal cell adenocarcinoma. The criteria for malignancy rest on histological assessment of margins and vascular invasion and must await excision of the lesion.

Occasionally, metastatic basaloid squamous cell carcinoma from the upper aerodigestive tract may be mistaken for a salivary gland primary. The solid variant of adenoid cystic carcinoma may resemble a basal cell tumour.

### **Warthin's tumour**

Interpretive difficulty typically arises in Warthin's tumour with squamous metaplasia. Infarction or inflammatory atypia in these benign tumours may give rise to cytological suspicion of squamous cell carcinoma.

### **Oncocytic tumours**

Oncocytes are cells with pink, granular cytoplasm and typically seen in benign tumours such as oncocytoma and Warthin's tumour. However, the appearances may be mimicked by acinic cell carcinoma and can make recognition of this rare malignant tumour difficult.

### **Low-grade lymphoma**

This can be a diagnostic dilemma in patients with long-standing Sjogren's syndrome. The development of low-grade (MALT) lymphoma in these patients may be difficult to detect on cytological appearances alone but may be supported by flow cytometry and PCR.

## **Low-grade mucoepidermoid carcinoma**

This may be difficult to distinguish from a mucocoele as the cells are bland in appearance without overt features of malignancy.

### **Diagnostic categories:**

It may be helpful to consider salivary gland lesions into C1-C5 diagnostic categories, which would be useful for clinical audit and also to give an idea about lesions that are equivocal for malignancy on FNA and core biopsy and for which formal excision and histological assessment is essential. The following categories are taken from the NHS Breast Screening Programme in the categorisation of lesions on breast FNA but may be applied to lesions of the salivary gland.

- C1 Non-diagnostic
- C2 Benign
- C3 Atypia, equivocal for malignancy
- C4 Suspicious for malignancy
- C5 Malignant

### **References**

- Stewart FW. The diagnosis of tumours by aspiration. *Am J Pathol* 1933. 9: 801-813
- Linsk JA. Aspiration cytology in Sweden: the Karolinska group. *Diagn Cytopathol* 1985. 1:332-335
- Saleh HA, Clayman L and Masri H. *Cytojournal* 2008;5:4
- Pratap R, Qayyum A, Ahmed N et al. Ultrasound-guided core needle biopsy of parotid swellings. *J Laryngol Otol* 2009;123(4):449-52
- Wan YL, Chan SC, Chen YL et al. ultrasound-guided core needle biopsy of parotid gland masses. *Am J Neuroradiol* 2004;25(9):1608-12
- G. Kocjan, A. Chandra, P. Cross, K et al. BSCC Code of Practice – fine needle aspiration cytology. *Cytopathology* 2009, 20, 283–296
- Ida AY, Hilmi OJ. An evidence based approach to the management of salivary masses. *Clin Otolaryngol.* 2009 Oct;34(5):470-3.

Zhang S, Bao R, Bagby J, Abreo F. Fine needle aspiration of salivary glands: 5-year experience from a single academic center. *Acta Cytol.* 2009 Jul-Aug;53(4):375-82.

O'Donnell ME, Salem A, Badger SA et al. Fine needle aspiration at a Regional Head and Neck Clinic: a clinically beneficial and cost-effective service. *Cytopathology.* 2009 Apr;20(2):81-6.

### **Typical diagnostic features of common lesions of the salivary gland**

A normal salivary gland is rarely aspirated and normal cytological material is usually encountered adjacent to an aspirated lesion. The normal elements include cohesive acini and occasional small groups of ductal epithelial cells. The acinar cells show a moderate to abundant amount of granular cytoplasm and small, round nuclei. Bare nuclei of acinar cells may be strewn in the background. Ductal epithelial cells occur in small honeycomb groups with scant cytoplasm and uniform oval nuclei.

#### **A. Non-neoplastic lesions**

**Mucus retention cyst** is characterised by variable amounts of thin or thick mucin and macrophages. If there is superadded acute inflammation, neutrophils may also be present. Salivary gland epithelial cells are usually scarce or absent.

**Lymphoepithelial cyst** contains lymphoid cells and mature squamous epithelial cells with or without inflammatory cells.

**Sialadenosis (sialosis)** consists of an abundance of normal salivary gland elements including numerous bare nuclei.

**Sialadenitis** may be dominated by an acute inflammatory exudate or a lymphocytic infiltrate with sparse epithelial cells in the chronic stage.

#### **B. Benign neoplastic lesions**

**Pleomorphic adenoma** contains a mixed population of epithelial and plasmacytoid or spindle-shaped myoepithelial cells, accompanied by fibromyxoid stroma. Due to variation in the proportions of the different

constituents, there may be difficulties encountered as the aspirate may bear resemblance to other tumours especially other benign tumours such as monomorphic adenomas.

**Warthin's tumour** is characterised by a combination of oncocytes, mixed lymphocytic population and a fluid background with debris and macrophages. Inflammatory changes may give rise to keratinising squamous metaplasia and degenerative changes which may lead to diagnostic difficulties.

**Oncocytoma** consists of cohesive groups of oncocytes with granular cytoplasm with round nuclei with small nucleoli but lack the lymphocytic infiltrate and fluid background of a Warthin's tumour.

**Sialadenoma papilliferum** shows papillary structures covered by oncocytes and accompanied by squamous metaplasia.

### **C. Malignant neoplastic lesions**

**Carcinoma ex-pleomorphic adenoma** shows moderate nuclear pleomorphism in epithelial elements and may be accompanied by necrosis. The malignant elements may be those of squamous cell carcinoma or adenocarcinoma. A background population of cells and stroma typical of a pre-existing pleomorphic adenoma may be seen.

**Mucoepidermoid carcinoma** may be low grade or high grade. Low grade tumours consist of moderate to abundant mucin, macrophages and mucus secreting epithelial cells with vacuolated cytoplasm. Squamous cells may be present in small numbers and are generally bland. In high grade tumours, these are prominent and more pleomorphic than in low grade carcinoma.

**Adenoid cystic carcinoma** shows groups of basaloid cells with scant cytoplasm and hyperchromatic nuclei. Sheets with cribriform architecture with luminal hyaline globules are prominent and the latter may be seen lying free in the background with adherent tumour cells.

**Acinic cell carcinoma** shows cellular smears with cells in sheets, microacinar groups and occasionally small papillary structures. The cytoplasm is granular and may be finely vacuolated with round nuclei and bland chromatin. A background lymphoid infiltrate may be conspicuous.

Bare nuclei may be seen as in normal salivary gland tissue but the cells are generally larger than normal and in sheets rather than as small round acinar groups.

**Epithelial/myoepithelial carcinoma** may show a biphasic pattern with epithelial and spindle cell elements. More commonly, clear cell change and myoepithelial bare nuclei are prominent.

**Polymorphous low-grade adenocarcinoma** shows a triad of infiltrative growth, multiple architectural growth patterns and cellular uniformity. Mucoïd and hyaline stroma with calcification may be seen. Clear cell and oncocytic change may also be present.

**Lymphoma** may arise on the background of lympho-epithelial lesions that occur in auto-immune conditions. High grade non-Hodgkin lymphoma is easily recognised by the presence of a monomorphic population of blasts but identification of low grade (MALT) lymphoma is more difficult to distinguish from a reactive lymph node and flow cytometry or immunochemistry should be performed when this is suspected clinically.

**Metastatic** deposits occur within the parenchyma or in intraparotid lymph nodes and may arise in the head and neck but from also distant sites.



## **Paediatric Cytology**

### **Helena Barroca, M D**

Serviço de Anatomia Patológica, Centro Hospitalar de S. João, Porto-Portugal. Email: hbarroca@gmail.com

---

#### **Introduction**

The approach to the cytological diagnostic of tumours and pseudotumoral lesions in paediatrics is based essentially on the use of fine-needle biopsy (FNB). Being an inexpensive low invasive technique with a high accuracy and diagnostic briefness FNB is regarded ideal to be applied in the paediatric setting. The use of a rapid, safe and accurate approach allowing the collection of enough material for complementary and sophisticated techniques such as flow cytometry, FISH, and PCR among others has enhanced the diagnostic power of this technique.

The advantages provided by FNB are optimized in the setting of a multidisciplinary team where cytologist, clinician and radiologist play leading tasks. A multidisciplinary approach is crucial in the correct planning of the biopsy. The most probable informative areas of the mass should be chosen to allow the most accurate diagnosis. It is critical that the pathologist has the perception of the numerous tissues crossed by the needle, that despite of the use of mandrel needles, are usually dragged on its way and be confounders. It is sometimes important to collect material from the neighbouring areas in order to compare with the tumour sample; this is particularly helpful in well-differentiated hepatic tumours.

Performing FNB in children is not different from a similar procedure in an adult . According to our experience, FNB should be performed preferably without aspiration, using a 25-gauge needle. Depending on the morphological features of the lesion (marked vascularization with risk of haemorrhage or marked desmoplasia) thinner (27-gauge) or larger (23-gauge) needles should be used. The mandrel needles are more difficult to control, but enable the split of the collected sample for various purposes, controlling the amount of ejected material from the needle, avoiding more passes

Despite the fact that FNB in children and in adults has a similar procedure some basic rules should be considered to minimize the discomfort (see Barroca H, Bom-Sucesso M. Fine needle biopsy with cytology in

paediatrics: the importance of a multidisciplinary approach and the role of ancillary techniques. *Cytopathology* [accepted for publication])

In an initial approach to diagnosis, the main goals of FNB are to separate benign from malignant clinical settings, and to proceed for a prompt therapy avoiding needless surgery, longer recovery times, and lengthy hospitalization.

In children, the most frequent non-tumour lesions target of FNB are of infectious cause, and often arise as a persistent lymphadenopathy. FNB should preferably be restricted to cases with a persistent enlarged lymph node or strong clinical suspicion of a specific infection or neoplasia, however in several situations it also is useful to reassure the parents' and the physician's fears of malignancy in a safe, timely, and cost-effective manner. Consequently a reactive cytological diagnosis is frequent. Other frequent cytological diagnosis are suppurative lymphadenitis granulomatous or not, or lymphadenitis due to mononucleosis. We will not address these subjects, which have been the subject of a separate workshop (M. Moonim).

Cancer is rare among those younger than 20 years of age; nevertheless a lump or a mass in a child is always a cause of concern and should be subjected to clinical evaluation.

In Europe about 15,000 children under 14 years are diagnosed with cancer each year.

Cancer in children encompasses a spectrum of different malignancies varying with the histology type, age, location, race, and gender (Figures 1 and 2 are reproduced from Barroca and Bom Sucesso. *Cytopathology* 2013)

Figure 1

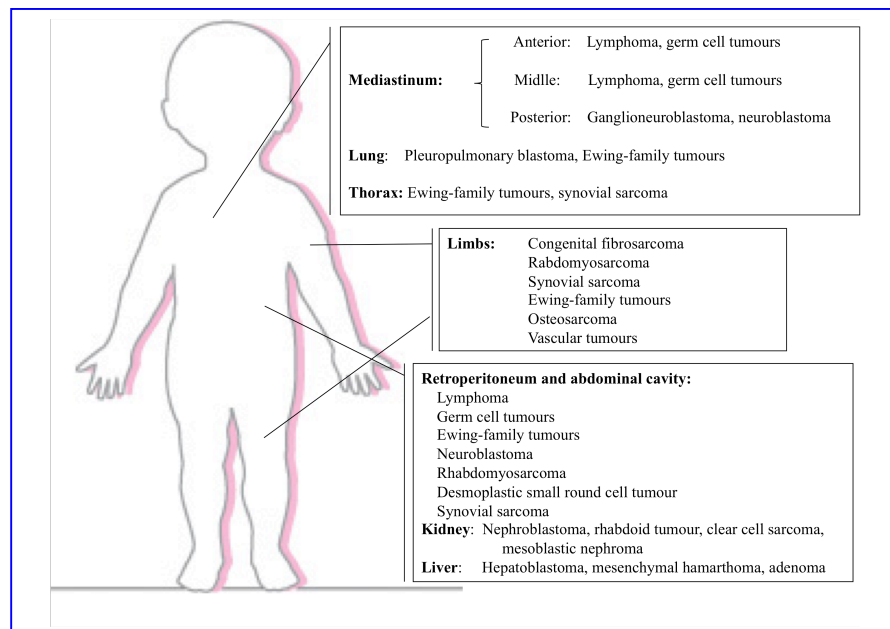
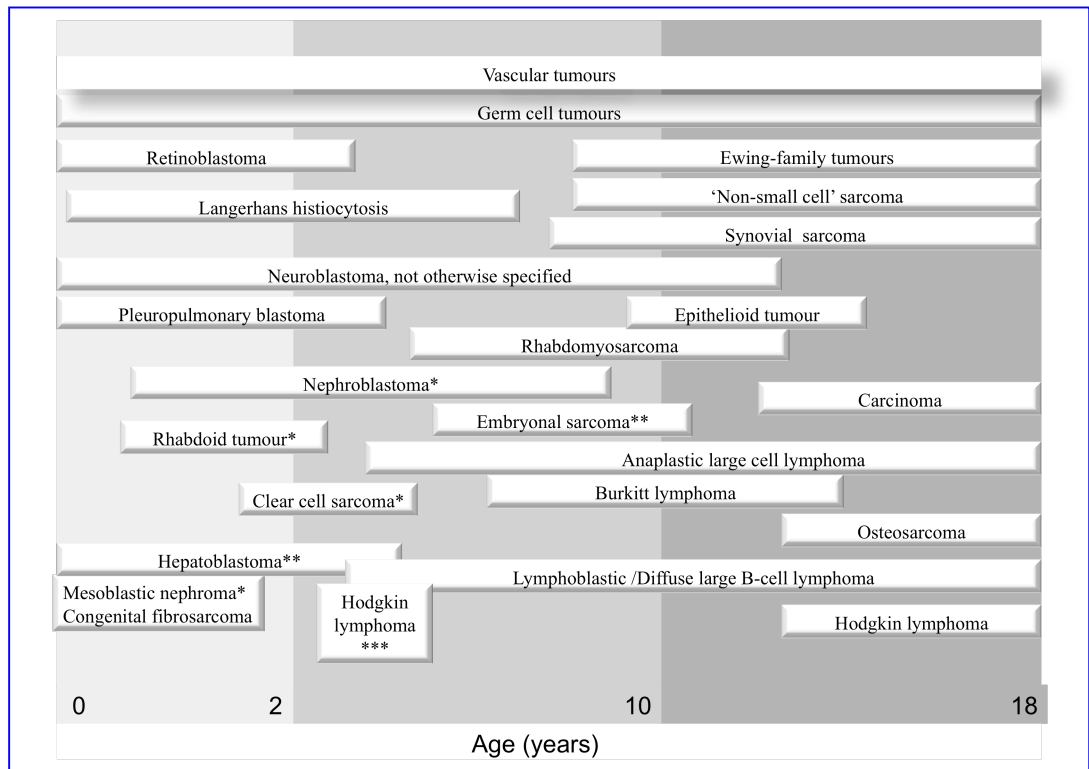


Figure 2



In this workshop we review essentially the cytological patterns that characterize the most frequent tumours in childhood.

## Paediatric tumours

### I. Renal neoplasms

#### *Congenital mesoblastic nephroma*

#### *Clinical features*

Typically diagnosed in the first three months of life, and 90% diagnosed in the first year, with male predominance. It represents 2 to 3% of paediatric renal tumours and is congenital (may be related with premature delivery, non-immune foetal hydrops and polyhydramnios).

Low-risk tumours (SIOP-2001-revised working classification of renal tumours of childhood); locally invasive; most cases have an excellent prognosis (5% of relapses), most due to incomplete excisions.

### ***Cytopathology***

- Variable cellularity with naked nuclei and spindle cells (fibroblastic/myofibroblastic ) singly or in cohesive fragments.
- Fibroblastic/myofibroblastic bland nuclei in a clear background; mucous-like material or necrosis in the background has been reported.
- Attention is required regarding entrapped renal tubules of periphery, or even deeper situated in the tumour, which can acquire primitive appearance (embryonal metaplasia), and act as confounders. For purpose of differential diagnosis, entrapped tubules are EMA positive and CD56 (NCAM) negative.

### ***Immunocytochemistry***

Positive: vimentin, smooth muscle actin, WTI (cytoplasm only)

Negative: desmin, CD56 (NCAM), CD10

### ***Genetic studies***

- Polysomy of chromosomes 8,11,17 and 20 (cellular variant only)<sup>#</sup>
- t (12; 15) - ETV6/NTRK3 fusion gene (cellular variant only)<sup>#</sup>
- Trisomy 11 – related to progression of classic to cellular type

<sup>#</sup> These aspects are shared with infantile fibrosarcoma

### ***Differential diagnosis (see relevant section)***

Predominantly stromal Wilms' tumour (WT), which is rare; clear cell sarcoma; rhabdoid tumour of the kidney

### ***Main points***

- Regarded as a low-grade fibroblastic sarcoma of the kidney; excellent prognosis

- Genetic studies have concluded that mesoblastic nephroma of classic and cellular types are different entities. Molecular similarities between the cellular type of mesoblastic nephroma and infantile fibrosarcoma have led to the belief that these two entities are the same, in different locations

### *Nephroblastoma (Wilms' tumour)*

#### ***Clinical features***

Common type of paediatric cancer (63% of paediatric cancers; 95% of all paediatric renal tumours). 1-2% has familial origin. WT is uncommon in neonates and is usually diagnosed before 6 years of age with a female predominance (unlike the majority of childhood cancers)

Palpable abdominal mass with pain (generally due to necrosis) is the most common presentation. Also, hypertension and haematuria.

Associated with hereditary conditions such as WAGR syndrome (Complete deletion of WT1 gene), Beckwith-Wiedemann syndrome (loss heterozygosity of chromosome 11p), hemihypertrophy, Denys-Drash syndrome (point mutation of WT1 gene).

#### ***Cytopathology***

- Classically, a triphasic morphologic pattern in differing proportions:
  - Blastemal cells: the most common cells in smears (due to looser cohesiveness they are easy to aspirate); small round blue cells, either singly or in diffuse sheets or rosettes; nuclear moulding; monotonous pale nuclei with very fine chromatin
  - Stromal component: primitive fibromyxoid stroma; rhabdomyoblastic differentiation; chondroid tissue, or any other type of mesenchymal differentiation
  - Epithelial cells: three-dimensional cellular groups, simulating tubules, papillary structures or poorly formed glomeruli; cells with high N/C ratio difficult to differentiate from blastemal cells when single; squamous metaplastic cells

Anaplasia – three criteria must be present in any of the tumour components: i) nuclear enlargement (greater than three times the size of

other nuclei); ii) hyperchromasia; iii) atypical mitotic features. When present, it should be considered to be representative of diffuse anaplasia and should be reported

### ***Immunocytochemistry***

Positive: vimentin (in blastemal cells); WT1 (in immature mesenchymal or blastemal cells (mesenchyma or blastema); Bcl2; cytokeratin (in epithelial component); NSE, synaptophysin, NB84, CD56 N-CAM (predominantly in non-epithelial blastemal cells) p53 (intense and extensive positivity suggests anaplasia)

Actin and desmin may be positive and are generally of no use in differential diagnosis

### ***Genetic studies:***

11p, 1p and 16q deletion/LOH is of prognostic relevance. Two main ways of tumourogenesis have been advanced:

#### **I: Wnt Pathway**

- TNNB1 and WT1 mutations appear to coexist in some cases of WT (6-20%)
- Association with intralobular nephrogenic rests; predominantly stromal type WT; early age onset (1-2 years old); association to WARG or Denys-Drash syndromes
- A novel gene, WTX located at chromosome Xq11.1, is also reported and generally coexist, to be mutated in WT. WTX operates in the AXINAPC complex, down-regulating the activity of beta-catenin
- LOI of IGF2 can be present

#### **II: IGF2 LOH Pathway**

- Loss of heterozygosity/imprint of IGF2
- Associated with perilobular nephrogenic rests, non-stromal WT and Beckwith–Wiedemann syndrome; affects older children (3-4 years old)

***Differential diagnosis (see relevant section)***

Neuroblastoma vs blastema; renal PNET vs blastema; lymphoma (Burkitt) vs blastema; rhabdomyosarcoma; rhabdoid tumour; clear cell sarcoma

### ***Main points for WT***

- Embryonic neoplasm derived from nephrogenic blastemal cells
- Less than 10% harbour a WT1 mutation; constitutional WT1 mutation and constitutional epigenetic mutation IGF 2 locus are predisposing factors
- It is the only renal tumour of childhood that may be bilateral (5% of the cases) and/or multifocal
- It is the only renal tumour of childhood associated with the presence of nephrogenic residues (30%)
- Diffuse anaplasia is present in 5% of cases, is not described in children younger than 6 months of age and is more likely over five years of age; it presents a more resistant cell line and is associated with extensive and strong immunoreactivity to p53 (p53 mutations)
- Metastasizes to lymph nodes in 15%, or to the lungs, liver or peritoneum; rarely to bone (1%)
- Recurrences are more frequent during the first two years after diagnosis

### ***Rhabdoid tumour***

### ***Clinical features***

- Rare tumour that accounts for less than 2% of paediatric renal tumours; 80% are diagnosed in the first year of age
- Hypercalcemia in 15%, associated with tumour production of parathormone and parathormone-like substances
- Often compromises the renal hilum at presentation
- No relation with Wilms' tumour or any syndrome
- First description in the kidney; is now well-documented in other locations such as liver, soft tissues, brain, genitourinary tract and skin

- Often metastasized at presentation (bone, brain and regional lymph nodes)
- 15% associated with synchronous or metachronous, genetically independent primary embryonal brain tumour (PNET-like neoplasm)
- High-risk tumours (*SIOP-2001 revised working classification of renal tumours of childhood*)

### ***Cytopathology***

- Round to polygonal rhabdoid-like dispersed cells or in clusters:
- Bare nuclei; cells with irregular nuclei and reticular chromatin; single eosinophilic macronucleoli surrounded by clear area; fragile, pale, and eccentric cytoplasm; intracytoplasmic eosinophilic inclusions

### ***Immunocytochemistry***

Positive: vimentin and cytokeratin coexpression (dot-positive), EMA, CD10

Variably positive: desmin (rarely), synaptophysin

Negative: myogenin, smooth muscle actin, CD56 (NCAM), CD57

Loss of nuclear INI1 positivity (most other tumours with rhabdoid features have detectable INI1 protein).

### ***Genetic studies:***

Variable findings: frequent monosomy 22; deletion at 22q11 in chromosome 22; biallelic inactivation of the tumour suppressor gene locus of *hSNF5/INI1* gene-association with alterations on the short arm of chromosome 11

### ***Differential Diagnosis (see relevant sections)***

Nephroblastoma, predominantly blastemal; rhabdomyosarcoma; neuroblastoma; renal PNET; renal cell carcinoma; lymphoma

### ***Main points***



- Initially described in the kidneys by Beckwith and Palmer as a possibly sarcomatous variant of WT; later described in soft tissues and other organs; most likely of primitive epithelial derivation
- Highly aggressive tumour: 82% with metastases at presentation; 90% of patients die within two years
- Association with synchronous or metachronous, genetically independent primary brain tumours
- Occur in patients with germline mutations in *hSNF5/INI1*
- A familial “rhabdoid predisposition syndrome” has been described in families with constitutional inactivating mutations of *hSNF5/INI1*.

### *Clear cell sarcoma*

#### ***Clinical features***

Rare renal tumour (3% of all paediatric kidney tumours) that occurs almost exclusively between the ages of 6 months and two years with male predominance; single centre tumour.

Propensity for bone (skull) and visceral metastases

High-risk tumour (*SIOP-2001 revised working classification of renal tumours of childhood*)

#### ***Cytopathology***

- Cellular smears: background of metachromatic mucoid-like material rich in glycoproteins seen in Giemsa-stained slides
- Large cells that are dispersed or in perivascular pattern; round, oval or short spindle bland nuclei with vesicular chromatin; nuclear grooves sometimes present; inconspicuous nucleoli, fragile and pale cytoplasm; myxoid stroma may be present; necrosis
- The presence of confounding renal tubules entrapped by the tumour that can appear in the smears may lead to erroneous diagnosis of WT (these tubules are CD56 (NCAM) negative and EMA positive)

#### ***Immunocytochemistry***

Positive: vimentin (moderate not strong: “a strong positive vimentin points away from CCSK”), CD56 (NCAM) (diffuse), Bcl2, CD117

Negative: EMA, desmin, CD15, WT1, CD10 (rarely positive)

***Genetic studies:***

- Recurring genetic defects have been reported: t(10;17), del(14)(q24.1q31.1)

***Differential diagnosis (see relevant section)***

Nephroblastoma (blastemal type); mesoblastic nephroma; neuroblastoma; PNET; rhabdoid tumour

***Main points***

- Undifferentiated sarcoma, nearly exclusively in the kidneys, also known as bone-metastasizing renal cell tumour
- No familial specific malformations, syndromes or genetic abnormalities associated
- Poor prognostic changes: necrosis; even low-stage tumours have poor prognosis; metastasis can occur 3 to 10 years after diagnosis

*Renal primitive neuroectodermal tumour  
Ewing family tumour (EFT)*

(See relevant section: soft tissue tumours other than rhabdomyosarcoma – small round cell tumours.)

*Renal cell carcinoma (RCC)*

***Clinical features***

Rare (less than 5% of paediatric renal tumours)

Paediatric associated subtypes:

1. *Renal medullary carcinoma*

2. *Xp11.2-associated RCC*

- represents 20% of renal cell carcinomas at paediatric and adolescent ages. Associated with different translocations involving chromosome Xp11.2 all resulting in gene fusion.

3. *t(6;11) translocation RCC*

4. In tuberous sclerosis (TSC) setting

- Kidney manifestations of TSC: angiomyolipomas, polycystic kidney disease, oncocytomas, RCC
- RCC in TSC: clear cell type; papillary; chromophobe; few cases reported; neoplastic cells with granular eosinophilic abundant cytoplasm
- Differential diagnosis between RCC NOS, oncocytoma and chromophobe RCC can be a challenge
- HMB45 negative, AE1/AE3 positive

5. *Neuroblastoma-associated RCC*

- Very unusual - 2.5% of renal cell carcinomas in young patients; described in survivors of childhood neuroblastoma

High-risk tumours (*SIOP-2001 revised working classification of renal tumours of childhood*)

***Cytopathology***

- Clear cell RCC: cytological picture similar to the adult
- RCC in children, Xp11.2-associated tumours
  - Large polygonal eosinophilic or clear neoplastic cells; prominent nucleoli; intracytoplasmic hyaline bodies and intranuclear inclusions; papillary pattern and psammoma bodies more frequent
- t(6;11) (p21;q12)- No reports on cytological features described.

***Immunocytochemistry***

*Clear cell RCC*

Positive: vimentin, EMA, CD10.

Negative: alpha-inhibin, melan A

*Xp11.2 RCC associated tumours*

Positive: renal cell carcinoma marker antigen, CD10, EMA (focal), vimentin (focal), TFE3 (nuclear).

Negative: S-100, desmin, cytokeratin.

*t(6;11)-related RCC*

Positive: HMB45, melan A.

Negative: cytokeratin.

**Genetic studies**

Contrary to what is observed in adults, childhood RCC is less frequently associated with mutations and deletion of the VHL genes

*Xp11.2-associated tumours*

- t(X;1)(p11.2;q21)-fusion TFE3 gene with PRCC gene
- t(X;1)(p11.2;p34)-fusion TFE3 gene with the *NonO*(p54<sup>nrb</sup>)
- t(X;17)(p11.2;q25)-Balanced translocation that fuses TFE3 gene with the ASPL gene-(same translocation of alveolar soft part sarcoma, in this last tumour it is unbalanced translocation is present).

*t(6;11)-associated RCC: t(6;11)(p21;q12)*

**Differential diagnosis**

*Adrenal cortical cell tumours* may be indistinguishable on histology. Positive: alpha-inhibin, melan A. Negative: EMA, vimentin. Positive

*Hepatic cells* can be confused with granular cells in clear cell RCC; better defined cytoplasmic borders; cytoplasmic iron; Hep-par 1:positive

**Main points**

- Xp11.2-associated tumours comprise a significant percentage of all renal carcinomas in children
- RCCs are rare in childhood: < 5% of paediatric renal tumours
- Cases of RCC arising in Wilms' tumours have been described
- Association with Von-Hippel-Lindau syndrome is less frequent in childhood

## II- Rhabdomyosarcoma

### *Clinical features*

- Accounts for around 50% of all childhood soft-tissue sarcomas
- Most arise from skeletal muscle, although they may also arise in viscera
- Those arising from skeletal muscle are particularly associated with genetic fusions
- About 65% are diagnosed in children (50% in the first decade); slight male predominance
- Rare familial forms are reported in association with Li-Fraumeni, basal cell nevus syndrome, pleuropulmonary blastoma, Beckwith-Wiedemann syndrome and neurofibromatosis
- Association with congenital anomalies of the central nervous system, genitourinary tract, gastrointestinal tract and cardiovascular system
- Association with low economic background
- Bimodal age distribution: peak at 3 - 5 years; and at 16 -17 years
- 95% of the cases in children belong to the alveolar or embryonal subtype
- Clustering of the primary tumour site, age and morphology (embryonal/alveolar) is a distinctive feature:

### *Embryonal*

In infants (may be congenital) ; mainly located in the orbit or perineum; also head neck, nasopharynx and genitourinary tract.

Rarely spreads to regional lymph nodes

### *Alveolar*

In adolescence; extremities, perineal and periorbital regions

Uncommon presentation: leukaemia-like

Metastasis to regional lymph nodes and along fascial planes

Symptoms depend on the localization

### *Cytopathology*

### *Embryonal (ERMS)*

- Clusters or isolated cells in a myxoid stroma and “tigroid” background in 20% of the cases (Giemsa staining)
- Lymphoglandular-like bodies present in 20%
- More cellular variation: whole range from primitive undifferentiated small round cells, mesenchymal cells (fusiform or stellate cells) to highly differentiated rhabdomyoblasts
- Binucleated or multinucleated tumour cells (strap cells) provide an important clue for differential diagnosis with other entities
- Presence of “tadpole” or “racket cells” and ribbon-like cells
- Nuclei with finely granular chromatin
- Cytoplasmic glycogen vacuoles

### *Alveolar (ARMS)*

- Cellular smears; tigroid background
- Background with apoptotic bodies can simulate a Burkitt cell lymphoma
- Loosely cohesive aggregates of uniform, small round blue cells
- Fine chromatin; inconspicuous nucleoli (occasionally can be prominent)
- Multinucleated neoplastic giant cells with eosinophilic cytoplasm
- Vacuoles of glycogen in the cytoplasm
- In some cells, a rhabdoid phenotype can be seen

Although these two main subtypes of rhabdomyosarcoma show some differences in cytomorphology, most authors do not rely on cytology alone, to make the differential diagnosis

Cytogenetic and molecular techniques together may be of great help; confirmation by means of histology is sometimes required

### ***Immunocytochemistry***

Positive: alpha-actin, desmin, myosin, myoglobin, myogenin, Myo-D1, HHF35, CD56 (N-CAM) (sometimes strongly positive ), WT1 (cytoplasm only)

Myogenin is more sensitive than Myo-D1 on formalin-fixed material: strong and diffuse nuclear expression mainly in alveolar type; MyoD1 is more sensitive than myogenin in frozen material. *Together with myogenin these are the more sensitive and specific markers of skeletal muscle*

‘Aberrant’ staining: NSE, synaptophysin, Leu7, cytokeratin, neurofilaments, S-100 protein and CD99

### ***Genetic studies***

*Alveolar subtype* has two main characteristic translocations:

- t(2; 13)(q35; q14) in 70% of the cases
- t(1;13)(p36;q14) in 10-20% of the cases
  - Associated with younger patients, better prognosis, involvement of extremities
- In 30% of the cases no translocation is found by RT\_PCR
- Solid variants are more likely to be PAX/FKHR negative
- Fusion-negative RMS behave similarly to ERMS

### ***Embryonal subtype***

- Loss of heterozygosity (LOH) at the 11p15 locus of the IGF II gene
- 1p deletion

Both subtypes of RMS have over-expression of the IGF II gene

### ***Differential diagnosis (see relevant sections)***

Peripheral neuroectodermal tumours (PNET); desmoplastic round cell tumour; neuroblastoma; lymphoma; rhabdoid tumour

### ***Main points***

- Overall five-year survival: 50%-75%
- Prognosis depends on:
  - Age at diagnosis; best survival is found when diagnosed between one and eight years of age

- Tumour site: two-year disease-free survival in orbital region is 77%, versus 24% for intrathoracic tumours
- Stage

***International prognostic classification of paediatric rhabdomyosarcoma***

*Superior prognosis:* botryoid; spindle

*Intermediate prognosis:* embryonal

*Poor prognosis:* alveolar; RMS with diffuse anaplasia; undifferentiated sarcoma

*Uncertain prognosis:* rhabdoid features

**III. Soft tissue tumors other than rhabdomyosarcoma**

**Small round cell lesions**

- Neuroblastoma, NOS
- Peripheral neuroectodermal tumour
- Desmoplastic small cell tumour

***Neuroblastoma NOS***

This term includes all sympathetic nervous system tumours of neuroblastic origin. It comprises a wide spectrum of continuous morphological features, ranging from undifferentiated neuroblastoma to ganglioneuroma, depending on the proportion of neuroblastematos (NB) and ganglioneuromatous (GNR) components.

***Clinical features***

- Third commonest extra cranial solid tumour of the paediatric age group.
- In 85% of the cases, it occurs in children under four years of age, and 50% under two years of age
- 65% of the cases present as an abdominal mass, with calcifications; although the adrenal is the most common site (50-80%), it can arise from any site containing sympathetic neural tissue



- Symptoms:
  - dependent on its location: huge abdominal masses give rise to abdominal distension and respiratory symptoms; retroperitoneal masses can extend along the nerves and vertebral openings into the spine cord, resulting in pain and paralysis (Dumbbell)
  - Non-specific symptoms: fever, irritability, anorexia and malaise
  - Paraneoplastic syndromes may be related to other hormonal substances produced by the neuroblastoma or to an immune response (e.g. antibodies against the tumour) as a cause of myoclonus: opisthotonus, Horner syndrome or Ondine's curse
- Metastases to regional lymph nodes, liver or bones at the time of diagnosis are common; Metastases to the lungs are rare
- Catecholamine secretion: 24h urine specimens should be tested for homovanillic acid (HVA) and vanillylmandelic acid (VMA), before or soon after excision, for future follow-up and as an indicator of differentiation and survival.
- Familial incidence is reported
- Associations with Beckwith-Wiedemann Syndrome, Hirschsprung's disease or neurofibromatosis, or as a complication of foetal hydantoin syndrome.

### ***Cytopathology***

- Distinguishing between the different types of neuroblastoma and ganglioneuroblastoma (INPC-classification) is impossible by FNA cytology, since this depends on the architecture and on exhaustive sampling of the tumour
- Its appearance depends on whether the NB or the GNR component predominates.

#### *Neuroblastomatous (NB) component :*

- Hypercellular smears; undifferentiated loose, round, small cells; round to oval nuclei with granular salt-and-pepper chromatin and inconspicuous nucleoli
- Background of fibrillary material; mitoses frequent; necrosis may be abundant

*Ganglioneuromatous* (GNR) component:

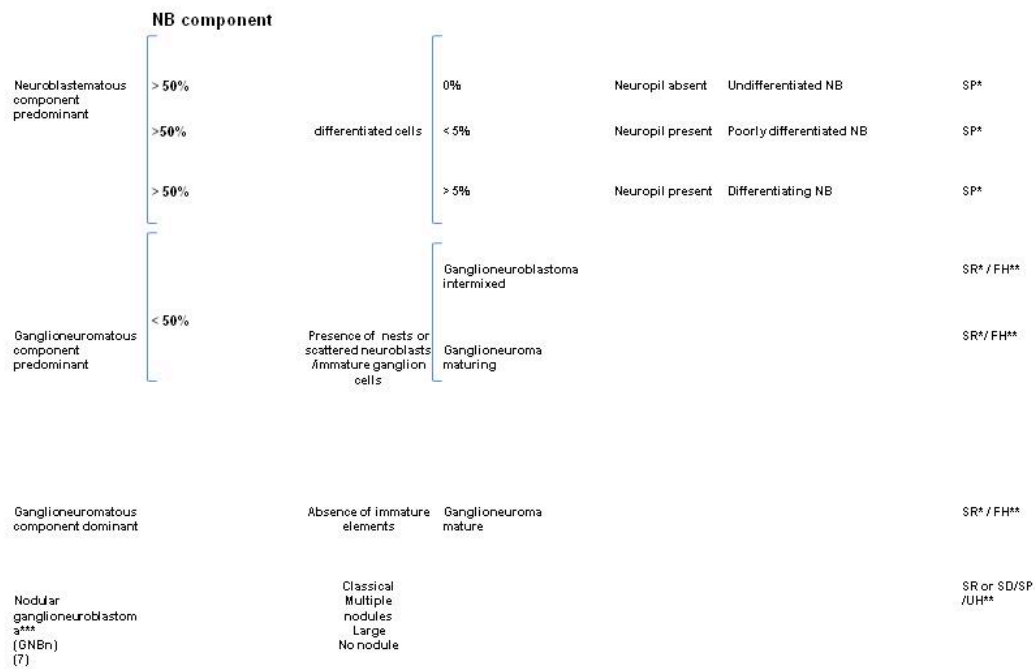
- Feeling of hardness while puncturing
- Hypocellular smears; mature or maturing ganglion cells; rare spindle nuclei corresponding to Schwann cells; collagen matrix

Although these two components are essential for classifying neuroblastic tumours, the cytological appearance more frequently has an intermediate pattern:

- Neuroblasts at varying degrees of maturation:
  - Undifferentiated neuroblasts: small uncommitted round cells
  - Maturing neuroblasts: neuroblasts with eccentric enlarged nucleus; small eosinophilic nucleoli; enlarged well-defined cytoplasm with Nissl substance
  - Immature ganglion cells: frequent binucleation; eccentric huge vacuolated nuclei with prominent eosinophilic nucleoli; enlarged well-defined cytoplasm with Nissl substance
- Variable amount of fibrillary neuropil (specific characteristic)
- Homer-Wright rosettes (not a specific characteristic, but they occur at a higher frequency than in other small cell tumours)
- Sparse Schwann cells- almost unrecognizable
- Variable numbers of mitoses and necrotic cells
- Calcifications can be seen

**Figure 3**

**International Neuroblastoma Pathology Classification  
(International Neuroblastoma Pathology Committee (INPC)  
classification)**



\*Original Shimada system (SR = stroma-rich; SP = stroma-poor; SD = stroma-dominant)

\*\*INPC grade (FH = favourable histology; UH = unfavourable histology)

• \*\*\* **GNBn:**

- Composite tumour with a favourable stroma-rich/stroma-dominant component and a nodular component of either a biologically favourable clone or an unfavourable clone, or both.
- Clinical behaviour (FH/UH) is dependent of the grade of the most unfavourable component present in the tumour.

- **Large cell type phenotype** – (large nuclei, clear chromatin, sharp nuclear membranes, and prominent nucleoli (7% of the cases); confers bad prognosis.

### ***Immunocytochemistry***

Positive: CD56 N-CAM, NB84, NSE, synaptophysin, chromogranin A, Leu7, GD2 (only in frozen material), CD117 (50%)\*

Negative: vimentin, CD99, actin: negative, desmin, cytokeratin

*\*some authors associate to better prognosis*

### ***Genetic studies:***

- N-*myc* expression and amplification
- Ploidy
- Deletion of chromosome 1
- 17q gains
- Double minute chromosomes
- Homogeneous staining regions
- TrKA, TrKB and TrkC expression (receptor proteins)

Prognostic markers

### ***Differential diagnosis (see relevant section)***

Lymphoma; rhabdoid tumour; alveolar rhabdomyosarcoma; desmoplastic small cell tumour; PNET

### ***Main points***

*Poor prognostic indicators:* age over 1.5 years, 1p36,33 deletion, 14p deletion, N-*myc* amplification, diploid, low expression of TrKA (maturation factor), undifferentiated morphology, high MKI and CD44 positivity (correlates with N-*myc* amplification: the greater the number of copies of N-*myc* is, the worse the prognosis will be)

*Favourable prognostic indicators:* age under one year, hyperdiploid/near-triploid, high levels of TrKA gene and no N-*myc* amplification

*Intermediate prognostic indicators:* older patients, near diploid/tetraploid, low levels of TrKA gene, no N-*myc* amplification and no 1p deletion

- TrKB expression: generally expressed in advanced tumours
- Stage IVs (any localized tumour, with liver or bone marrow metastasis, but with no bone involvement); these cases are generally seen in infants and usually have a good prognosis
- Neuroblastoma in situ: incidental finding at autopsy in infants less than three months of age
- Extra-adrenal tumours are better differentiated and have better prognosis
- Low urinary VMA/HVA ratio is associated with poor outcome (sign of lack of differentiation)

*Peripheral neuroectodermal tumours  
(PNET/Ewing's sarcoma)/Ewing family  
tumours (EFT)*

***Clinical features***

- Mainly affect adolescents and young adults; no sex predilection
- One-third of cases has a major nerve involvement with neurological symptoms
- Common sites: paravertebral region, lower extremities and retroperitoneum

***Cytopathology***

- Discohesive or in groups of monomorphic small round cells
- Dimorphic population of smaller and darker cells and lighter staining cells
  - Lighter cells have pale chromatin, small nucleoli and membranous cytoplasmic blebs (Diff-Quick staining)
  - Darker cells have condensed chromatin and scarce cytoplasm (they are probably cells in degeneration)
- Absence of neuropil and ganglion cells
- Rosettes are seen, even though rarer than in neuroblastoma

- Tigroid background can be seen
- Necrosis

### ***Immunocytochemistry***

Positive: CD99 (membranous pattern: not specific but the most useful marker); caveolin-1 (even in CD99 negative cases); FLI-1 (nuclear-only, 70% of the cases); cytokeratin (focal positivity in 20%); AE1/AE3; p63 (some cases); synaptophysin (focal); NSE

Negative: CD56 (NCAM); CK20 (useful differentiating from Merkel tumour); chromogranin (most cases)

<b>List of CD99-positive tumours</b>
Ewing/PNET
Alveolar rhabdomyosarcoma
Desmoplastic small round-cell tumour
Atypical teratoid rhabdoid tumour
Synovial sarcoma
Mesenchymal chondrosarcoma
Merkel cell carcinoma
Non-Hodgkin lymphoma

### ***Genetic studies***

- t(11;22)(q24;q12) in 90% of the cases
- t(21;22) or t(7;22) - 15% of the cases
- C-*myc* over expression
- N-*myc*: no expression

### ***Differential diagnosis (see relevant section)***

Neuroblastoma; atypical teratoid rhabdoid tumour; Wilms' Tumour; alveolar rhabdomyosarcoma; lymphoma; small cell osteosarcoma; desmoplastic small cell tumour; undifferentiated Synovial sarcoma

### ***Main points***

*PNET and Ewing's Sarcoma* are the well and poorly differentiated ends of a spectrum of round-cell sarcomas with a partial neuroectodermal phenotype - Ewing family of tumours (EFTs)

- Neural crest origin
- 1% of all soft tissue sarcomas
- PNET and Ewing's sarcoma are related entities and nowadays form a single group of bone and soft-tissue tumours (electron microscopic, immunohistochemical and cytogenetic features are remarkably similar)
- Surgical resection and/or radiotherapy and chemotherapy have increased survival from less than 10% to 40%
- Lack of responsiveness to preoperative chemotherapy

#### *Prognosis:*

- Depends on stage; site; size; age; response to therapy
- EWS exon7 fusion with FLI1 exon 6)- better prognosis
- Deletion 1p-poor prognosis
- P53 mutation - poor prognosis

### ***Desmoplastic small cell tumour***

#### ***Clinical features***

- Children and young adult; usually in males
- Abdominal pain
- Abdominal location with predilection for pelvic region, as solitary or multiple nodules; ascites is a constant feature
- Cases have been described in lungs, pleura, ovaries, pancreas, testes, cranial fossa, parotid, and soft tissues
- Lymph node metastases are rare

#### ***Cytopathology***

- Single and clusters (sheets or three-dimensional groups) of monomorphic small round cells
- Neoplastic cells with uniform nuclei; nuclear moulding; fine granular chromatin; inconspicuous nucleoli; sparse cytoplasm; stromal fragments
- Other patterns: rhabdoid, signet ring or rosettes

### ***Immunocytochemistry***

Positive: coexpression of desmin (dot), EMA, AE1AE3, CAM5.2, vimentin and WT1

Negative: Myo-D1, smooth muscle actin; chromogranin; CD99 (membranous staining negative, some authors report in 35% of the cases cytoplasmic positivity)

### ***Genetic studies***

- t(11;22)(p13;q12)

### ***Differential diagnosis (see relevant section)***

PNET; alveolar rhabdomyosarcoma; neuroblastoma; other small round cell tumours, depending on the site of origin: pancreatoblastoma, pancreatic neuroendocrine tumours, hepatoblastoma and Wilms' tumour

### ***Main points***

- Some authors suggest a probable origin from a primitive mesothelial cell-“*Mesothelioblastoma*”, based on the immunoexpression of desmin, WT1, vimentin and cytokeratins by both mesothelium and this entity
- Extremely aggressive neoplasm: average survival less than three years
- Weak response to chemotherapy

## **IV - Germ cell tumours**

- Teratoma
- Germinoma/seminoma
- Endodermal sinus tumour
- Embryonal carcinoma
- Choriocarcinoma



Bimodal age distribution (peaks at 2 and 15-20 years of age).

Most common entities:

*Children under two years of age*

- Teratoma and endodermal sinus tumour are the most common entities
- Most tumours occur at extragonadal sites: sacrococcygeal, head, neck, retroperitoneum, stomach, liver, central nervous system, heart and vagina
- Mature teratomas in children are mostly cystic (dermoid cyst); 15% bilateral

*Adolescence*

- Gonadal and mediastinal sites are the most common locations at this age
- At this age, they represent 15% of all mediastinal cysts and tumours
- There is a well-known association between haematological malignancies and mediastinal germ cell tumours
- Seminoma is a rare tumour at this age or younger
- Most testicular tumours are mixed germ cell tumours
- Ovarian malignancies account for about 1% of all childhood malignancies (the majority are germ cell tumours)

*Teratoma*

**Mature teratoma** is not a cytological diagnosis. The presence of an immature or malignant component cannot be ruled out through FNA.

***Cytopathology***

- Representation of epithelial or mesenchymatous components
- Presence of cellular elements not normally represented in that location
- Presence of immature tissues (blastemal, cartilage, etc.)
- Presence of malignant cells
- Cystic component

### ***Immunocytochemistry***

- Stains correspond to the tissues present

### ***Modern diagnostic techniques***

- Non-contributory

### ***Differential diagnosis***

All the tissues and tumours that may be present in mature, immature and/or malignant teratomas

### ***Main points***

- Tumours that arise from a germ cell after first meiotic division

## ***Germinoma/seminoma***

### ***Clinical features***

- Generally in adolescents
- The least aggressive of the malignant germ cell tumours in children
- Frequent in the ovary and pineal region; testicular tumours rare at this age
- Rarely as a component of a teratoma
- 15% bilateral (in patients with gonadal dysgenesis)
- Serum elevation of lactic dehydrogenase and isoenzyme-1

### ***Cytopathology***

- Moderately to highly cellular smears; poorly cohesive cells; stripped nuclei; large single cells with single central vesicular nuclei and prominent nucleoli; fragile cytoplasm (glycogen)
- Tigroid background (Giemsa stain); absent in the atypical forms

- Epithelioid cells, occasionally granulomas; multinucleated histiocytic cells; lymphocytes (rare in the atypical forms)
- Necrosis is not characteristic

### ***Histochemical stains***

- PAS positive; PAS-diastase negative

### ***Immunocytochemistry*** (see Table 1)

Positive: placental alkaline phosphatase (PLAP); vimentin; CD117; OCT4

Negative: cytokeratin (generally negative but some authors have reported 15% of cases are positive); EMA; alpha-fetoprotein: negative

### ***Differential diagnosis*** (see relevant section and Table 1)

Large cell lymphoma; embryonal carcinoma

### ***Main points***

- Five-year survival for pure forms is 80-90%; usually occurs as pure form
- Metastasizes to the opposite ovary, retroperitoneal nodes and peritoneal cavity
- Association with choriocarcinoma, yolk sac tumour or embryonal carcinoma worsens the prognosis

## ***Yolk sac tumour***

### ***Clinical features***

- Children and young adults
- Serum elevation of alpha-fetoprotein
- Frequently develops from a teratoma
- More common in the ovary than in the testis

- Rare locations: retroperitoneum and mediastinum
- No association with endocrine symptoms
- Malignant-5-year survival-66.6%

***Cytopathology*** (Macroscopically aspirates can carry translucent and viscous material)

- Moderate to high cellularity; cells embedded within the matrix
- Single cells or in spherical or papillary aggregates; large polygonal cells; hyperchromatic nuclei; frequent nucleoli; pale cytoplasm with vacuoles of glycogen
- Mucoïd background; dense basement membrane-like matrix
- Eosinophilic hyaline globules in intra or extracellular location
- Necrosis

***Immunocytochemistry*** (see Table 1)

Positive: alpha-fetoprotein; alpha-1-antitrypsin (focal); CEA; cytokeratin; PLAP

Negative: human chorionic gonadotropin: vimentin; CD30

***Histochemical stains***

- Eosinophilic hyaline globules (PAS-diaïtase positive)

***Differential diagnosis*** (see relevant section and Table 1)

Embryonal carcinoma

## *Embryonal carcinoma*

***Clinical features***

- Peak incidence in the first decade
- Pure forms are rare in children

- More common in the testis than in the ovary
- High serum human chorionic gonadotropin (HCG)
- Less commonly elevated serum alpha-fetoprotein
- Isosexual precocity: vaginal bleeding, amenorrhea, hirsutism

***Cytopathology***

- Cellular smears
- Similar appearance to an adenocarcinoma
- sheets, nests, glandular or papillary formations; ragged-edged cell clusters; large pleomorphic cells; irregular nuclei; coarse chromatin; multiple prominent nucleoli; sparse cytoplasm
- Syncytiotrophoblast cells
- Necrotic background

***Immunocytochemistry*** (see Table 1)

Positive: cytokeratin; CD30; alpha-fetoprotein (focal); OCT4; PLAP (focal in syncytiotrophoblast cells)

Negative: EMA

***Modern diagnostic techniques:*** Non-contributory

***Differential diagnosis (see relevant section and Table 1)***

Germinoma; carcinoma; yolk sac tumour

**Table 1. Immunophenotype of germ cell tumours**

Marker:	Seminoma	Yolk sac tumour	Embryonal carcinoma	Choriocarcinoma
AE1/AE3)	+/-	+	+	+
PLAP	+	+	+	+/-
AFP	-	+	+/-	-
Beta-HCG	- (except in giant cells)	-	-	+
S-100 protein	-	-	-	-
LCA	-	-	-	-
CD30	- (rarely +)	-	+	-
OCT4	+	-	+	-

AFP, alpha-fetoprotein; HCG, human chorionic gonadotropin; LCA, leukocyte common antigen; PLAP, placenta-like alkaline phosphatase; + positive; +/- positive or negative; - negative.

### **V - Liver**

- Inflammatory pseudotumor
- Hepatoblastoma
- Hepatocellular carcinoma
- Embryonal sarcoma

### *Inflammatory pseudotumour*

#### ***Clinical features***

- Possible symptoms: fever, abdominal pain, vomiting, diarrhoea and jaundice
- Hypergammaglobulinemia

### ***Cytopathology***

- Inflammatory cells (plasma cells, eosinophil's and neutrophils)
- Macrophages
- Fibroblasts/myofibroblasts
- Reactive atypical hepatocytes or atypical bile duct epithelial cells

### ***Immunocytochemistry***

Non-contributory

### ***Modern diagnostic techniques***

- Non contributory

### ***Differential diagnosis***

- Mesenchymal hamartoma

### ***Main points***

- Excision is advised

## ***Hepatoblastoma***

### ***Clinical features***

- Most frequent primary liver tumour in children (40% of all paediatric hepatic tumours and 55% of all malignant tumours)
- 88% occur under 5 years of age; 68% during the first two years of life
- Male and Caucasian predominance
- 60-70% in right lobe
- Associations with: prematurity, low birth weight (< 1500 g), Beckwith- Wiedemann syndrome, trisomy 18 syndrome, familial polypoid adenomatosis and hemi hypertrophy
- 80-90% have significant elevation of serum alpha-fetoprotein

- lower levels of alpha-fetoprotein may indicate a poorer prognosis
- Paraneoplastic syndromes: thrombocytosis, human chorionic gonadotropin production (virilisation) and osteoporosis

### ***Cytopathology***

- High cellularity- Cells occur singly or in trabeculae, acini, cords and rosettes (anaplastic subtype)
- Small hepatocytes with high N/C ratio with centrally placed nuclei and prominent nucleoli
- Sparse to moderate granular cytoplasm (depends on the degree of differentiation)
- Nuclear moulding (anaplastic subtype)
- Nuclear pyknosis
- Hematopoietic elements (more frequent in the foetal subtype)
- Mesenchymal elements: osteoid

### ***Immunocytochemistry***

Positive: Low molecular weight cytokeratin's, Alpha-fetoprotein (75%), (may be negative in anaplastic subtype), EMA (except for the anaplastic subtype), CEA (canaliculus staining pattern) (*except for the anaplastic subtype*), chromogranin A (focal) (50%), HepPar1, vimentin (75%), (*generally negative in anaplastic subtype*), HCG (giant cells), glypican 3, HMB45, CD99: positive, CD56 (NCAM), Neuroendocrine markers, NB84, Bcl-2.

Negative: Desmin (except in teratoid tumours), CD45

### ***Genetic studies***

- No consistent pattern of chromosomal anomalies
- P53 gene mutation

### ***Differential diagnosis***



- Hepatocellular carcinoma (embryonic and macrotrabecular subtypes), metastatic Yolk sac tumour, rhabdomyosarcoma, small round blue cell (“metastatic” tumours, e.g. neuroblastoma , Wilms’ tumour, lymphoma, Ewing’s sarcoma), especially in anaplastic subtypes

### ***Main points***

- Embryonal tumour derived from pluripotent hepatic stem cells
- High incidence of trisomy 20 and trisomy of all or part of chromosome 2
- Main prognostic factor: complete resect ability
- Other prognostic factors: tumour size, stage and multifocality
- Foetal type is the only histological subtype that leads to changes in therapy regarding stage I tumours
- Distant metastasis in 20% of the patients at diagnosis
- Five-year survival rate is 75%

## ***Embryonal sarcoma***

### ***Clinical features***

- Usually occurs between 6-10 years of age as an abdominal mass
- fever and pain
- Serum alpha-fetoprotein levels are normal

### ***Cytopathology***

- Cellular smears with mesenchymal clusters in a myxoid background
- Heterogeneous population of tumour cells (spindle, oval, pleomorphic and multinucleated giant cells)
- Nuclei with intense pleomorphism and coarse chromatin
- Moderate amount of cytoplasm with poorly defined limits
- Hyaline globules in the background or intracytoplasmic

- Haemorrhage and necrosis

### ***Immunocytochemistry***

Positive: Anti-chymotrypsin, alpha-1-antitrypsin: positive

Variable positivity: Desmin, muscle-specific actin, vimentin: variable

Negative: Alpha-fetoprotein (hyaline globules), myogenin

### ***Genetic studies***

- Rearrangements of chromosomal band 19q13.4
- t (11; 19) (q13; q13.4)

### ***Differential diagnosis***

- Mesenchymal hamartoma, embryonal rhabdomyosarcoma, hepatoblastoma (mixed and embryonal)

### ***Main points***

- Occasionally arising in mesenchymal hamartoma,
- Primitive mesenchymal neoplasm
- Treatment: complete surgical resection
- Death within two years due to direct extension
- Metastasis to lung and bone

## **VI - Adrenal tumours other than neuroblastoma**

- Adrenal cortical adenoma/carcinoma
- Pheochromocytoma

### ***Adrenal cortical adenoma/carcinoma***

### ***Clinical features***

- The adrenal cortical cell is part of endocrine epithelia and has the capacity of hormone production: steroids, glucocorticoids and mineralocorticoids.
- Adenomas-rarely functional- incidental detection
- Carcinomas- 50% are hormone secreting - Cushing syndrome or virilisation of women patients (androgen secretion).
- 0.2% of all paediatric malignancies.
- More common at ages of 0-5 years, but presents bimodal occurrence: in infancy and in adolescence
- Presentation: abdominal mass with pain and fever; Presentation and prognosis differ from those of adults
- Associations with
  - Li-Fraumeni, Beckwith-Wiedemann, Ver-Morrison, cancer family syndrome, SBLA (S- sarcoma; B- breast and brain neoplasm; L- leukaemia, laryngeal and lung carcinoma; A- adrenal cortical carcinoma) and foetal alcohol syndrome
  - Genitourinary anomalies, neurofibromatosis, pigmented nevi, brain tumours and hemi hypertrophy
  - Endocrine abnormalities (virilisation and Cushing's syndrome) is common in children, although feminization and Conn's syndrome are rare

### ***Cytopathology***

- Cellular smears with sheets and discohesive neoplastic cells separated by delicate vessels
- Lipidic background-Giemsa stains
- Polygonal or plasmacytoid monomorphic cells with bland nuclei and pleomorphic cells, with irregular outline, coarse chromatin and evident nucleoli
- Pleomorphism can be exuberant- not associated with malignancy
- Nude nuclei (single or in morular pattern)
- Nuclei are eccentric with pseudo inclusions. Nucleoli can be prominent

- Cytoplasm ranging from eosinophilic (more frequent in carcinomas) to clear and vacuolated (more frequent in adenomas) and can have hyaline globules
- Mitoses are variable
- Sarcomatoid appearance generally seen in poorly differentiated carcinomas
- There are no cytological criteria for distinguishing benign from malignant cases, although a bubbly lipid background has been reported by some authors to correlate with benign nature(7)

### ***Immunocytochemistry***

Positive: D11 (nuclear) in 80%, Ad4BP (nuclear adrenal 4 binding protein)- (100% in adrenal cortical carcinomas), A103 (melan A)- (100% in adrenal cortical carcinomas ), Inhibin A, NSE, synaptophysin, CAM 5.2, Hep Par1, S100 protein and Bcl-2.

*Cytokeratin: decreased expression relative to the degree of malignancy*

*Vimentin: increased expression relative to the degree of malignancy*

Negative: chromogranin, CEA, EMA, CD10, CK7, CK20, HMB45

### ***Differential diagnosis***

- Renal cell carcinoma, hepatocellular carcinoma, pheochromocytoma

### ***Main points***

- Functional tumours do not carry worse prognosis, unlike in adults
- A poor outcome is more common in the adolescent age group
- Survival, in malignant cases, depends on the stage and the completeness of surgical resection
- Children with Beckwith-Wiedemann Syndrome have better prognosis. There are no cytological criteria for distinguishing benign from malignant cases, although a bubbly lipid background has been correlated by some authors with benign nature

## *Pheochromocytoma*

### ***Clinical features***

- Known as “10% tumour”: 10% bilateral; 10% extra-adrenal; 10% malignant; and 10% in children.
- Peak age is the fifth decade
- 90% are sporadic and 10% have a familial history of multiple endocrine tumours (MEN syndromes)
- Presentation: paroxysmal hypertension, headaches, nausea, vomiting, diaphoresis, palpitations, tremors, fatigue, anxiety, chest and abdominal pain and visual disturbances.
- Children are more affected with clinical symptoms than adults are; 90% suffer from hypertension, convulsions, polydipsia or polyuria
- Bilateral cases are more frequent in children
- Secretion of norepinephrine and epinephrine; rare cases with production of ACTH or VIP

### ***Cytopathology***

- Hypercellular smears, with single cells and loose clusters, displaying a huge variation in cell size or shape
- Cells have nuclear pseudo inclusions and a poorly defined reddish granular cytoplasm (Giemsa stain)

### ***Immunocytochemistry***

Positive: Neurofilaments, vimentin, chromogranin, synaptophysin, CD56, N-CAM, S-100 protein ( sustentacular cells), NSE

*Cytokeratin: controversial; sparse when present*

Negative: EMA, alpha-inhibin

Indicators of malignancy : p53: positive and Ki-67: positive

### ***Genetic studies***

- 10% of sporadic pheochromocytomas harbour somatic mutations involving proto-oncogene
- MEN 2a and 2b are associated with the chromosome 10q11.2-*ret* proto-oncogene site

### ***Differential diagnosis***

- Sarcomatoid renal cell carcinoma, adrenocortical carcinoma

### ***Main points***

- Malignant pheochromocytomas are slow-growing neoplasms: five-year survival rate of 40-50%
- Common sites for metastasis: lymph nodes, bone and liver
- Mutations of the neurofibromin gene seem to contribute to the development of pheochromocytomas in patients with Von-Recklinghausen's disease

## **VII- Others**

- Juvenile granulosa cell tumour
- Nasopharyngeal carcinoma

### ***Juvenile granulosa cell tumours***

#### ***Clinical features***

- Account for half of paediatric/adolescent sex cord stromal cell tumours
- Children and young adults (80% before age of 20 years)
- Presentation: Sexual precocity and irregular uterine bleeding (due to oestrogen production), abdominal distension, pain or ascites.
- Association with enchondromatosis (Ollier's disease), Mafucci syndrome, infantile dimorphism and ambiguous genitalia
- 2% are bilateral

### ***Cytopathology***

- Cellular smears and loose clusters or single granulosa and theca cells
  - Granulosa cells have homogeneous round centrally placed nuclei with fine chromatin and conspicuous nucleoli, paucity of nuclear grooves. Atypia may be present; Cytoplasm is pale and vacuolated cytoplasm with indistinct cell borders
  - Theca cells are elongated cells and hyperchromatic nuclei
- Macrophages

### ***Immunocytochemistry***

Positive: Inhibin (granulosa cells), calretinin, vimentin, smooth muscle actin (theca cells)

Negative: EMA

### ***Electron microscopy***

- Prominent smooth endoplasmic reticulum
- Numerous mitochondria
- Large lipid droplets in cytoplasm

### ***Genetic studies***

- Trisomy 12 (common to other stromal cell tumours)

### ***Differential diagnosis***

- Adult granulosa tumour, yolk sac tumour/ embryonal carcinoma, fibroma/ thecoma

### ***Main points***

- Most tumours are benign, however with a propensity for late recurrence
- Prognostic factors: stage, size, rupture, nuclear atypia and mitotic activity

## *Nasopharyngeal carcinoma*

### ***Clinical features***

- Demographics
  - Africa: associated with EBV; common in children
  - South China: most common cancer in adults; rare in children
  - US: rare in adults and children
- Associated with HBV infection and repeated exposure
- Presentation as a lymph node metastasis is frequent
- Other sites of metastasis: bone, bone marrow, liver and lungs

### ***Cytopathology***

- Sheets and clusters of undifferentiated epithelial cells
- Vesicular nuclei and prominent nucleoli
- Sparse eosinophilic cytoplasm
- Inflammatory cells: lymphocytes (often T cells) and plasma cells

### ***Immunocytochemistry***

- Positive: Keratins, EMA, EBV, EBER, CD23, CD30
- Variable: CEA, S-100 protein

### ***Genetic studies***

- Over expression of p53

### ***Differential diagnosis***

- Large cell lymphoma, Hodgkin's disease

### ***Main points***

- Treatment: radiation therapy
- Good prognostic factors: younger age, lower stage, metastases limited to the upper neck and no involvement of central nerve system